

Optional Brachytherapy Imaging Study for RTOG 0417

This brachytherapy imaging study is highly encouraged but not mandatory.

- A digital image study (CT or MR) obtained for one or all fractions of brachytherapy will be acceptable.
- The ability to perform an imaging study prior to each insertion will be institution and third-party payer dependent.
- For LDR insertions, images with the applicator in place should be obtained prior to loading of cesium 137 or after the cesium 137 has been removed.
- For HDR patients, images should be obtained before or after the first fraction is delivered, and if possible, all of the 5-6 insertions.
- All applicators must be FDA or institutional IRB approved.
- The applicator type and manufacturer must be listed on the digital data submission form when the images are submitted electronically to the ITC for later review.

1.0 Dose Prescription

- The dose prescription must follow the guidelines listed in the protocol.

2.0 CT Images

- CT compatible applicators are preferred.
- If CT compatible applicators are not available, efforts to minimize artifact should be considered. Use of bone rather than soft tissue windows is helpful in minimizing artifact and assessing the surrounding soft tissues around the tandem. The vaginal portion of the applicator may produce too much artifact to visualize the walls of the rectum and bladder.
- IV and rectal contrast *may* be used for patients undergoing CT to better opacify the bladder and rectosigmoid.
- If oral contrast is use, the scan should be performed 30 minutes after administration.
- If vaginal packing is used, it should be saturated in 1:10 dilution of Conray-60 contrast agent or equivalent or should have radio-opaque stripe sewn in the packing
- The Foley catheter bulb should be inflated with air rather than contrast for the imaging procedure.
- Contiguous slices of 3 mm or less are to be used for CT scan study. An AP and lateral scout should also be obtained. The slices should extend from at least 1 cm above the tip of the tandem to the bottom of the ischium. A table feed of 3 mm will be used for helical/spiral CT. The reconstruction interval is 3 mm.

3.0 MRI Images

- If MR is to be used, a non-ferromagnetic applicator must be used and should be tested in the MRI scanner prior to insertion into a patient to make sure that there is no interference with the magnetic field.
- Non-ferromagnetic cervical markers are required.

3.1 Pretreatment MRI: High resolution:

- T2 weighted MRI with and without fat saturation is to be used for imaging. Other sequencing (eg. T1 weighted MRI with Gd contrast) can be used to supplement these data sets. The details of protocol for MR imaging for cervical cancer is provided in **Appendix I**.
- MRI-compatible applicators that simulate conventional applicators are required. When moving a patient between the imaging unit and the treatment room, a secure method of fixing the applicator with respect to the patient is required.

3.2 MRI at the time of (any) intracavitary brachytherapy with MRI compatible applicator in place:

- Infuse 150 cc of water into the bladder via foley catheter with 7cc of water in foley bulb.
- High resolution, T2 weighted MRI with and without fat saturation with applicator in place is to be used for imaging. Other sequencing (eg. T1 weighted MRI with Gd contrast) can be used to supplement these data sets. The details of protocol for MR imaging for cervical cancer is provided in Appendix I.

- Imaging to define tumor and normal structures must be performed with the patient in the treatment position, with all treatment conditions duplicated as closely as possible. For example, if the patient is to be treated supine with the knees slightly elevated then imaging should be performed with the patient in the same position. Markers for localizing tumor margins or normal tissues, if used, must be MR-compatible. Images must be obtained 5 cm superior to the most cephalad part of the brachytherapy sources to 2 cm inferior to the most caudad part of the brachytherapy sources. Imaging is to be performed for one or more brachytherapy insertions.

3.3 Target Volume Nomenclature:

3.3.1 Gross Tumor Volume (GTV):

- GTV(I) is defined as the gross primary tumor volume as defined through MR imaging at the time of brachytherapy.
- GTV is defined as GTV(I), plus any clinically visualized or palpable tumor extensions.
- GTV+CX is defined as the GTV plus the entire cervix. (**Figure 1**) If the entire cervix is involved by tumor, the GTV and the GTV+CX will be the same.
- The tumor volume may change dramatically during the course of therapy. Hence, the GTV is to be defined at the beginning of treatment (before external beam or brachytherapy) and redefined at the time of insertion.

3.3.2 Clinical target volume (CTV):

- CTV is considered to be the combination of the primary clinical target volume (pCTV), and the regional lymph node sites or regional CTV (rCTV).
- pCTV includes the GTV in addition to the entire uterus, parametrial tissues to the pelvic sidewall and at least 2 cm of normal vagina beyond any clinically assessed gross tumor.
- rCTV includes a minimum margin of 1.5 cm around the contoured iliac vessels (surrogate for iliac lymph node sites) and any normal appearing or enlarged lymph nodes.

3.4 Contouring Requirements:

- GTV, GTV_(I), GTV+CX, CTV, pCTV, rCTV.
- Organs at risk - the bladder wall, the rectal wall (which may include the sigmoid colon), and the small intestines are also to be contoured. For small intestines, contour the intestines (excluding the sigmoid colon) using the outermost limit of all the intestines, rather than individual bowel loops, within 5 cm from any brachytherapy source. Some contouring software allows the operator to contour the outer surface of the organ wall and subtract the lumen of the organ, leaving only the wall itself. Without such software, it is necessary to contour the inner and outer walls of the organ continuously, connecting the two with a short "bridge" through the organ wall. (**Figure 2**)

4.0 Dose reporting:

- Report Integrated reference air kerma (IRAK) and doses to conventional points (point A, ICRU bladder, ICRU rectum, pelvic side wall, vaginal surface and vagina at 5mm depth points).
- Report the D₁₀₀, D₉₅, D₉₀ (dose to 100%, 95%, or 90% of) GTV, GTV_(I), GTV+CX, CTV, pCTV, rCTV and the V₁₀₀ (% of GTV covered by Point A dose).
- For normal tissues, report the maximum dose at any point within the bladder wall, rectum wall and small bowel along with the maximum dose to a contiguous 1 cm³, 2 cm³, and 5 cm³ volume of the bladder, rectum and small bowel respectively.

5.0 Digital Data Transmission:

Data is to be transmitted electronically to the ITC (**see digital instructions link**).

Appendix I: MR Imaging of Cervical Carcinoma

Normal MR Appearance:

The zonal anatomy of the cervix is best demonstrated on T2-weighted sequences. The mucosa of the endocervix is seen as a central stripe of high signal intensity that is surrounded by low signal intensity stroma. The peripheral cervical tissue demonstrates intermediate signal intensity, similar to myometrium. On gadolinium contrast-enhanced T1-weighted images, the inner mucosal epithelium and the pericervical tissue enhance more than the inner cervical stroma. The parametrium, connective soft tissue that is adjacent and lateral to the uterus and not covered by peritoneum, is vascular and contains many efferent lymphatics. The uterine arteries and the distal ureters pass through the lateral parametrial tissues. The parametrium demonstrates intermediate signal intensity on T1-weighted images and varying degrees of high signal intensity on T2-weighted images.

MR Imaging Appearance of Cervical Carcinoma

The superior soft tissue contrast provided by MR imaging compared to CT or US makes it the best possible imaging modality for the assessment of tumor volume and extent. On T2-weighted sequences, cervical cancer is seen as a hyperintense mass relative to normal stroma. On T1-weighted images cervical cancer is usually isointense to normal stroma and may not be detectable. With dynamic contrast imaging, cervical cancer shows early contrast enhancement.

MRI Sequences:

Both T1- and T2-weighted sequences are required for evaluation of the female pelvis. T1-weighted imaging provides excellent contrast between fat and soft tissue and is the optimal sequence for assessment of lymphadenopathy. T1-weighted sequences are also useful for characterization of soft tissues. Both hemorrhage and fat demonstrate high signal intensity on T1-weighted images, and a fat-saturation sequence can be used to differentiate the two. With fat saturation techniques, fat appears dark (fat-saturated) and hemorrhage remains high in signal intensity. T2-weighted sequences are optimal for demonstrating the zonal anatomy of the uterus and cervix, identifying ovaries, and depicting pathologic conditions. Conventional spin echo T2-weighted imaging has been replaced by fast spin echo (FSE). T2-weighted techniques which require less imaging time and therefore reduce motion artifact [51-53]. Breath-hold single-shot FSE pulse sequences, which decrease imaging time and motion even further, have recently been developed [51, 54].

Intravenous contrast enhancement, with gadolinium chelates (0.1 mmole/kg), may be useful in characterizing and better depicting the extent of lesions as well as in assessing vascular anatomy. Gadolinium chelates can be used safely in patients with allergies to iodinated contrast media and/or renal impairment. Gadolinium is routinely used in the evaluation of endometrial and ovarian disease. Gadolinium is not routinely used in the staging of cervical cancer as it has not been shown to improve overall staging accuracy [35-37]. However, it can help differentiate viable tumor from debris and areas of necrosis, and assess for bladder or rectal involvement.

MRI protocol for cervix cancer

Imaging will be performed on a high field strength 1.5 Tesla magnet with a phased array surface coil as it provides higher signal-to-noise ratio resulting in improved spatial resolution than the generalized body coil [55]. For optimum imaging results, movement artifact must be kept to a minimum. Bowel motion is limited by having patients fast for 4-6 hours prior to the study and if there are no medical contraindications, administration of an anti-peristaltic agent (glucagon 1 mg IV or IM or buscopan 20 mg IV or IM) just before the examination. Abdominal binding is used to reduce the anterior abdominal wall motion. Respiratory compensation is used to minimize breathing artifact. A Foley catheter will be inserted into the bladder and the bladder distended with saline prior to the examination. The degree of bladder distension will be the same as that during treatment. The area of coverage should extend from the aortic bifurcation down through the introitus with 24-28 cm field of view (FOV), 5mm slice thickness with 1 mm gap, 16 kHz bandwidth, 256-521 x 256 matrix and NEX of 2. An echo train length (ETL) of 8 will be used for the FSE T2 sequences. The sequences for a diagnostic staging examination are as follows:

- (a) localizer, sagittal plane
- (b) Sagittal plane of section, FSE T2-weighted image; repeat with single shot FSE T2 if motion artifact present.
- (c) Axial plane of section, FSE T2-weighted image; repeat with single shot FSE T2 if motion artifact present.
- (d) Axial plane of section, T1-weighted image; scan to renal hilum if pelvic lymphadenopathy present.
- (e) Only if cancer extension to the urinary bladder or rectum is suspected after reviewing the non-contrast images, gadolinium will be administered and a sagittal plane of section, post-contrast T1 will be obtained.

Sequences required for assessing position of applicator: (b) and (c) as above with applicator in place. Can use single shot FSE T2, if adequate.

The MR imaging protocol is summarized in Table 1.

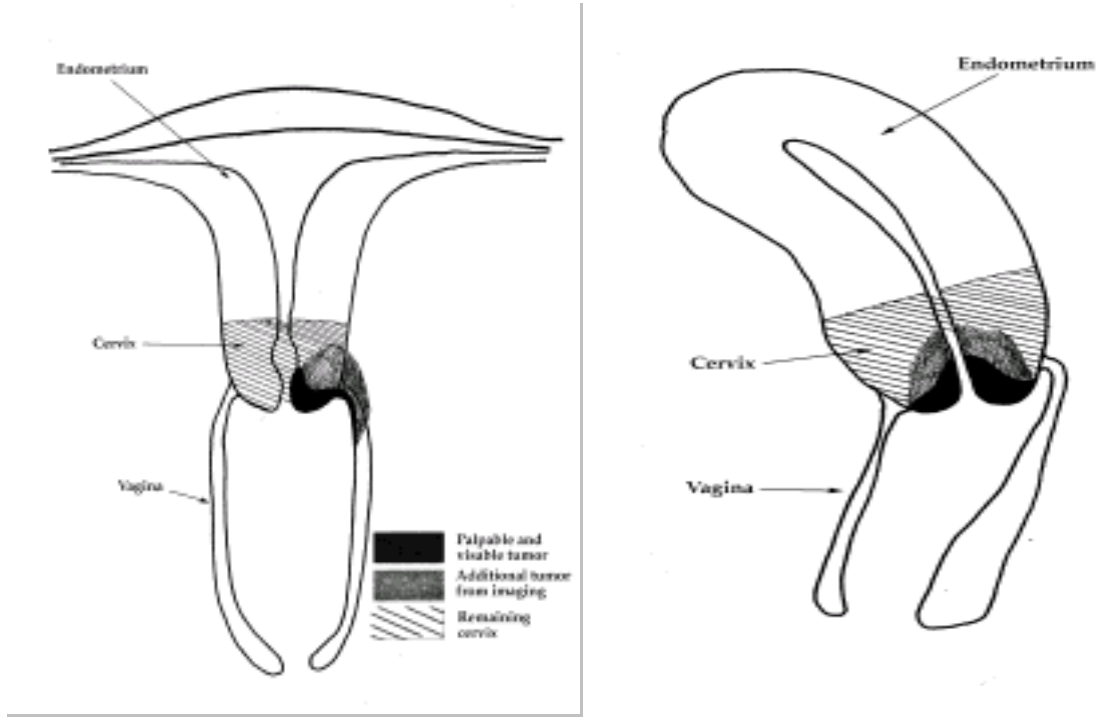


Figure 1: Definition of GTV, $GTV_{(I)}$ and $GTV+CX$.

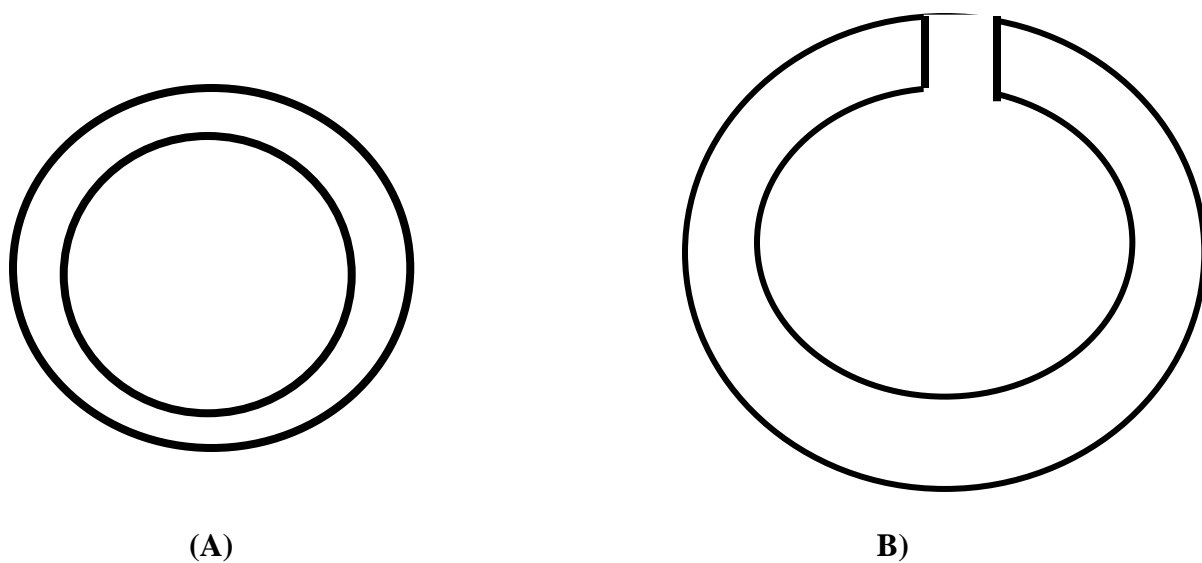


Figure 2: (A) When contouring the bladder wall, contour the outer surface of the bladder wall and subtract the lumen of the bladder, leaving only the wall itself, if the contouring software allows volume subtraction. (B) Without such software, it is necessary to contour the inner and outer walls of the bladder continuously, connecting the two with a short “bridge” through the bladder wall.

Table 1: Protocol for cervical carcinoma MRI for staging and brachytherapy

POSITION:

Supine

CENTERING POINT:

SPECIAL INSTRUCTIONS:

SEQ	COIL	PLAN E	TR	TE	FLIP ETL	BW (kHz)	FOV (cm)	SLIC ETHICK	GAP	MATRIX Frq/phase	NE X	IMAGING OPTIONS	
1. FSE T2	pelvic	Sagitta	2000	85		16	36-48	10	0	256/256	1		Localizer.
2. SE T1	pelvic	Axial	5-700	10-15		16	24-28	5	1	256/256	2	St:Slap RC	Extend to renal hilum if pelvic nodes present
3. FSE T2	pelvic	Axial	4000	85	8	16	24-28	5	1	512/256	2	St:Slap SPF NPW	Frq AP to reduce abd. wall motion artifact
4. FSE T2	pelvic	Sagitta	4000	85	8	16	24-28	5	1	512/256	2	St:Slap SPF NPW	Frq AP to reduce abd. wall motion
Options													
1.SSFSE T2	pelvic	Sag+/- Ax	∞	100		62.5	24-32	5	1	256/256	0.5		Breath hold salvage T2
2. FSE T2	pelvic	Obi Cor	4000	85	8	16	24-28	5	1	512/256	2		If cervical mass not well seen on ax or cor
3. SE T1 post gad	pelvic	Sag+ax	5-700	10-15		16	24-28	5	1	256/256	2	St:Slap RC Post gad	NPW for sag. sequence. If suspect bladder & rectal involvement.

