

Upper Abdominal Normal Organ Contouring Guidelines

RTOG Consensus Panel

2013

**Salma K. Jabbour, M.D.¹, Sameh A. Hashem, M.D.^{2,3}, Walter Bosch, D.Sc⁴,
Tae Kyoung Kim, M.D.⁵, Steven E. Finkelstein, M.D.⁶, Bethany M. Anderson,
M.D.⁷, Edgar Ben-Josef, M.D.⁸, Christopher H. Crane, M.D.⁹, Karyn A.
Goodman, M.D.¹⁰, Michael G. Haddock, M.D.¹¹, Joseph M. Herman, M.D., M.
Sc.¹², Theodore S. Hong, M.D.¹³, Lisa A. Kachnic, M.D.¹⁴, Harvey J. Mamon,
M.D., Ph.D.¹⁵, Jason R. Pantarotto, M.D.¹⁶, Laura A. Dawson, M.D.²**

1. Department of Radiation Oncology, The Cancer Institute of New Jersey, University of Medicine and Dentistry of New Jersey, Robert Wood Johnson Medical School, New Brunswick, NJ
2. Department of Radiation Oncology, Princess Margaret Hospital/University of Toronto, Toronto, Ontario, Canada
3. present address: Department of Radiation Oncology, King Hussein Cancer Center, Amman, Jordan
4. Washington University School of Medicine, St. Louis, MO
5. Department of Medical Imaging, University Health Network, Mount Sinai Hospital and Women's College Hospital, University of Toronto, Toronto, Ontario, Canada
6. 21st Century Oncology Translational Research Consortium Scottsdale, AZ
7. Department of Human Oncology, University of Wisconsin School of Medicine and Public Health, Madison, WI
8. Department of Radiation Oncology, University of Pennsylvania School of Medicine, Philadelphia, PA
9. Department of Radiation Oncology, The University of Texas MD Anderson Cancer Center, Houston, TX
10. Department of Radiation Oncology, Memorial Sloan-Kettering Cancer Center, New York, NY
11. Department of Radiation Oncology, Mayo Clinic, Rochester, MN
12. Department of Radiation Oncology, Johns Hopkins University School of Medicine, Baltimore, MD
13. Department of Radiation Oncology, Massachusetts General Hospital, Harvard Medical School, Boston, MA
14. Department of Radiation Oncology, Boston University Medical Center, Boston, Massachusetts
15. Department of Radiation Oncology, Dana Farber Cancer Institute, Boston, Massachusetts; Brigham and Women's Hospital, Boston, MA
16. Department of Radiation Oncology, The Ottawa Hospital, University of Ottawa, Ottawa, Ontario, Canada

Abbreviations

- Roman numerals refer to liver segments
- L_: left
- R_: right

- CA: celiac artery
- CHA: common hepatic artery
- IMV: inferior mesenteric vein
- LHV: left hepatic vein
- LPV: left portal vein
- MHV: middle hepatic vein
- PV: portal vein
- RHV: right hepatic vein
- RPPV: right posterior portal vein
- RTAPV: right anterior portal vein
- SA: splenic artery
- SMA: superior mesenteric artery
- SMV: superior mesenteric vein
- SV: splenic vein

Lung_R

Lung_L

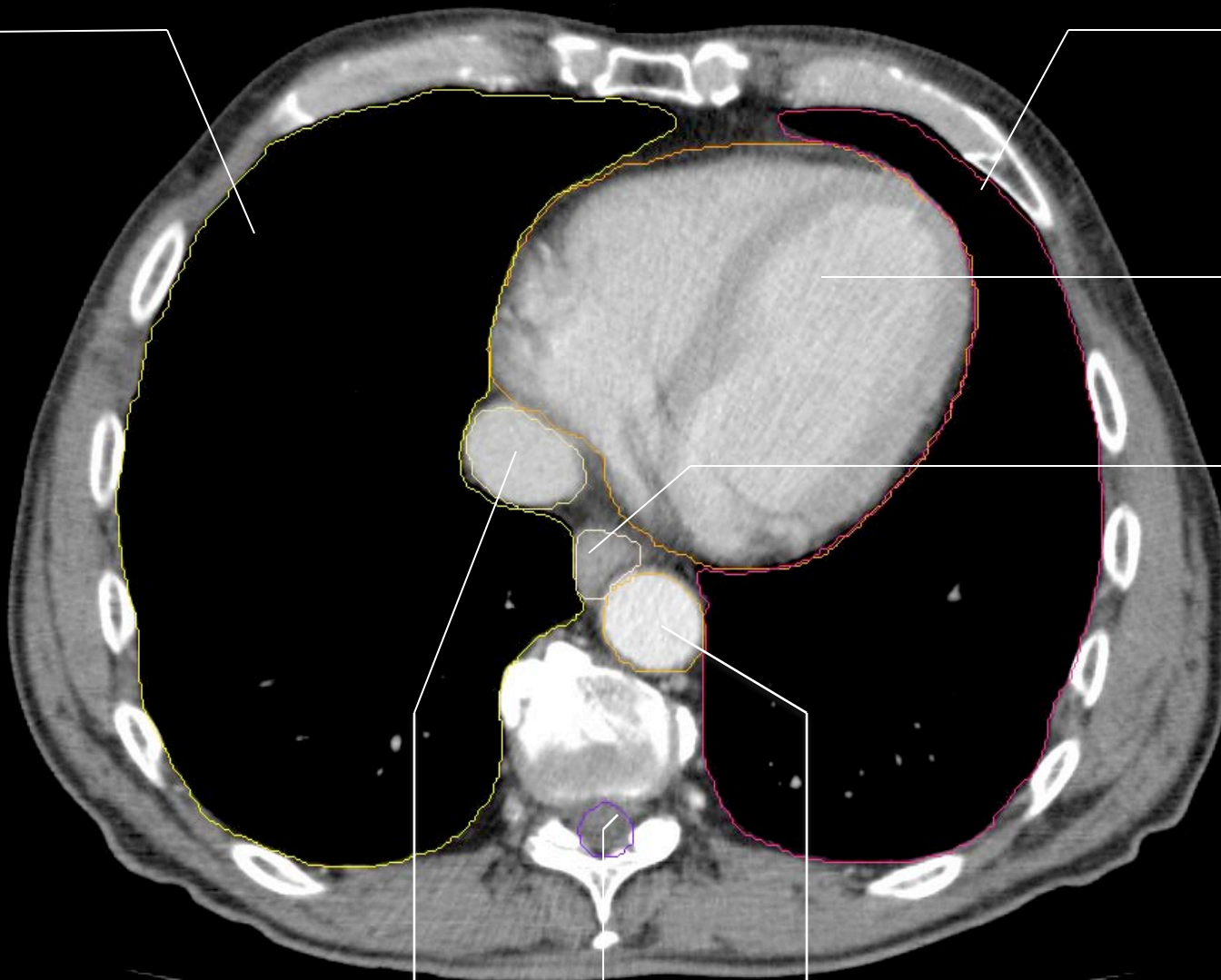
Heart

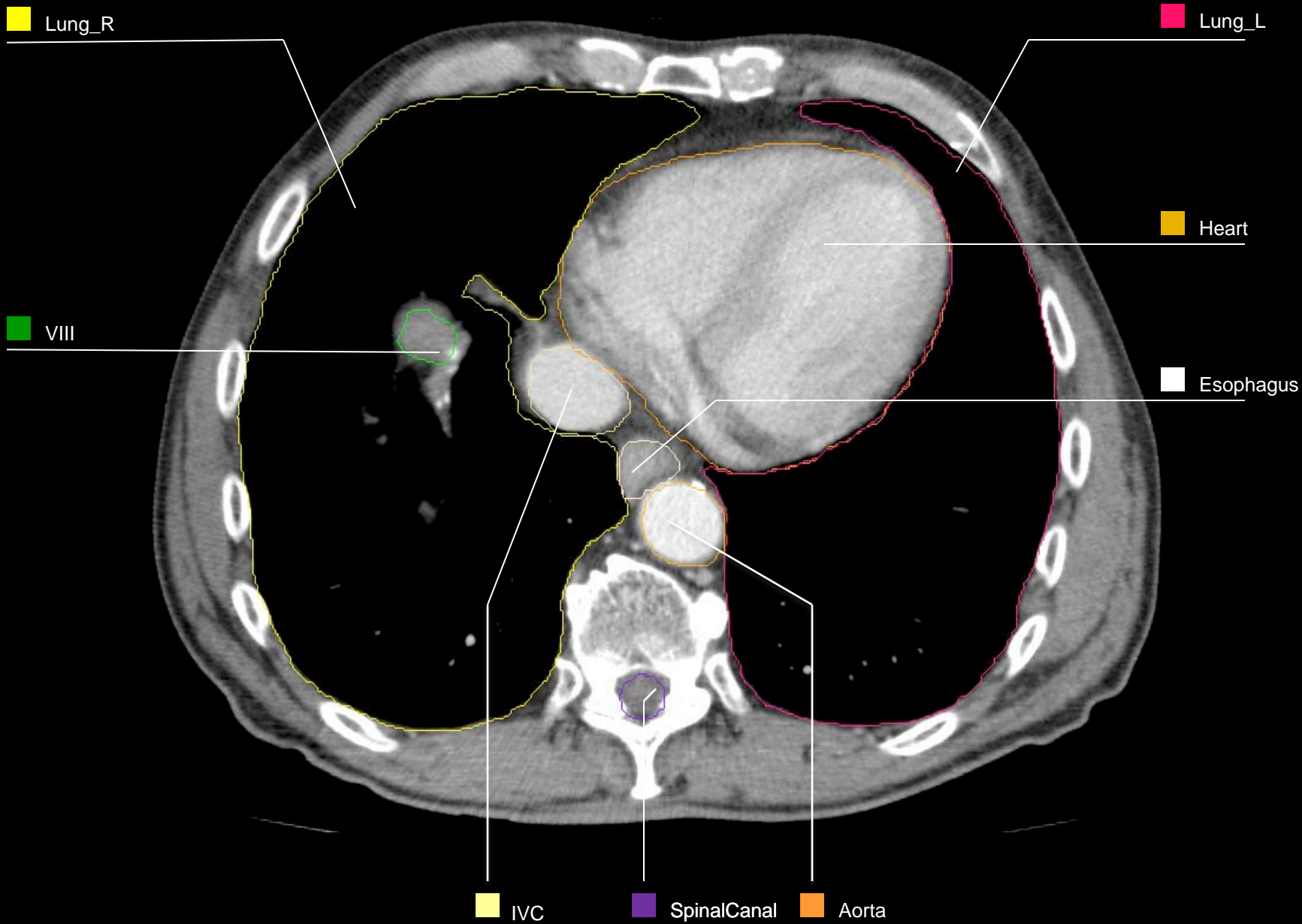
Esophagus

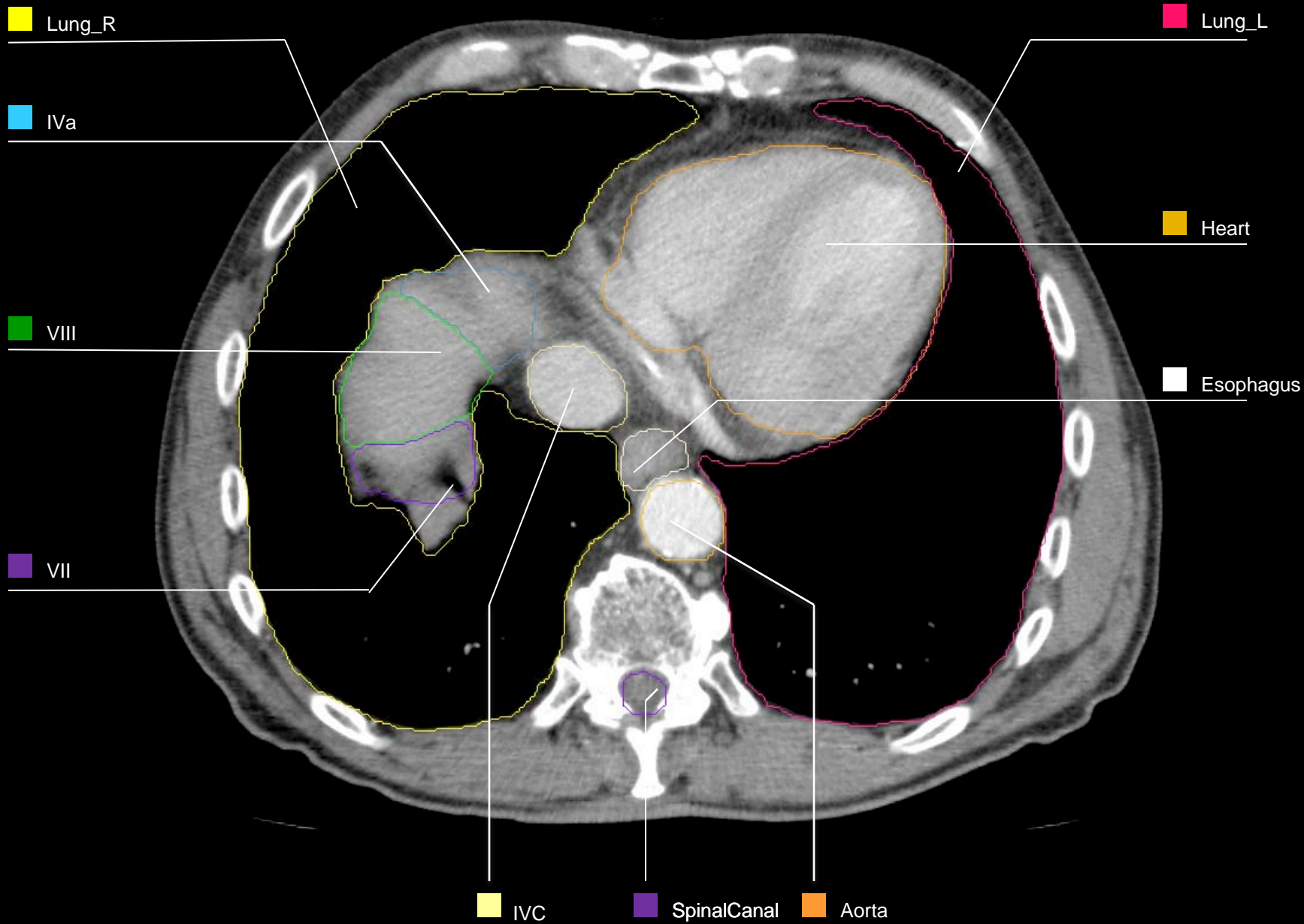
IVC

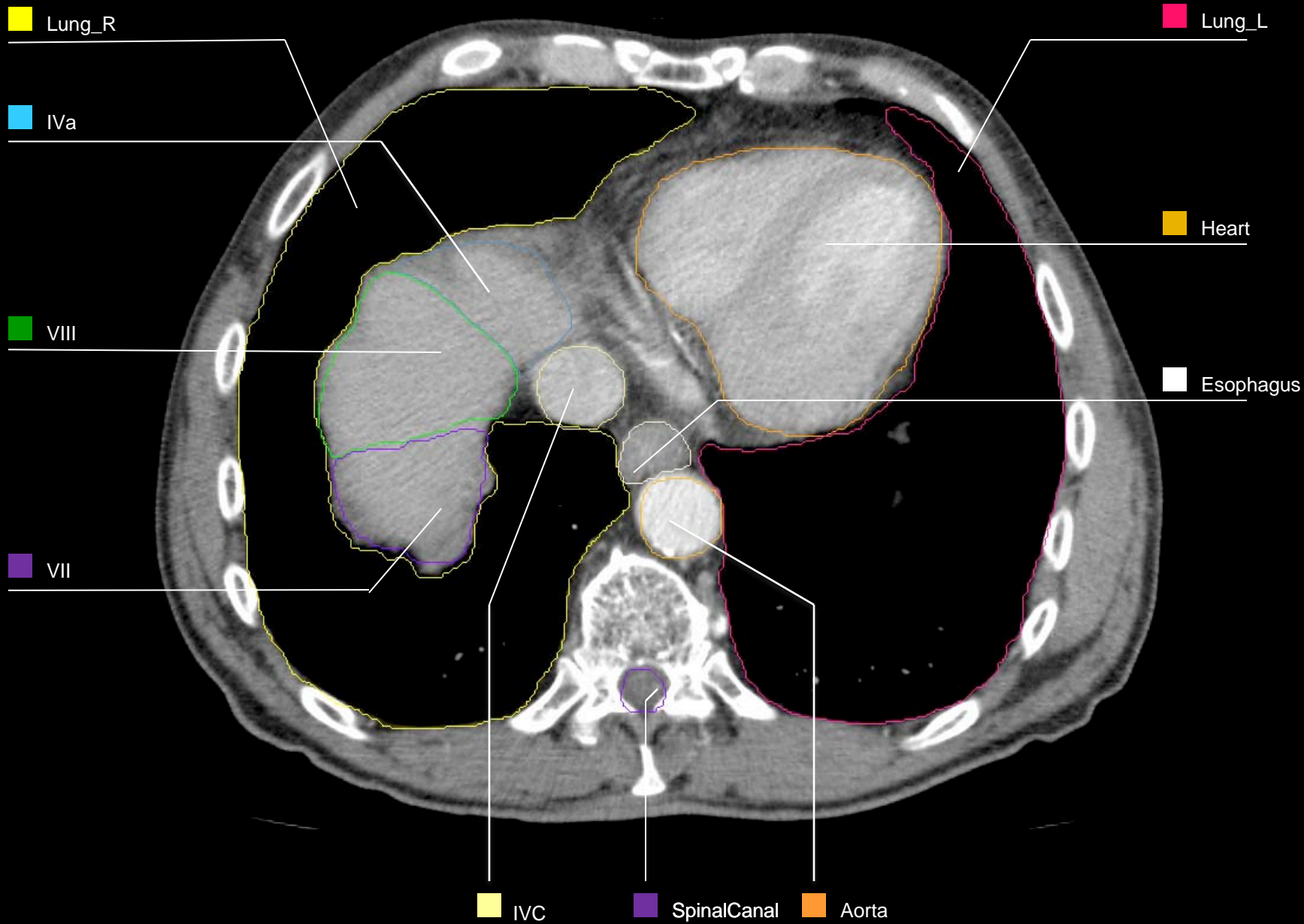
SpinalCanal

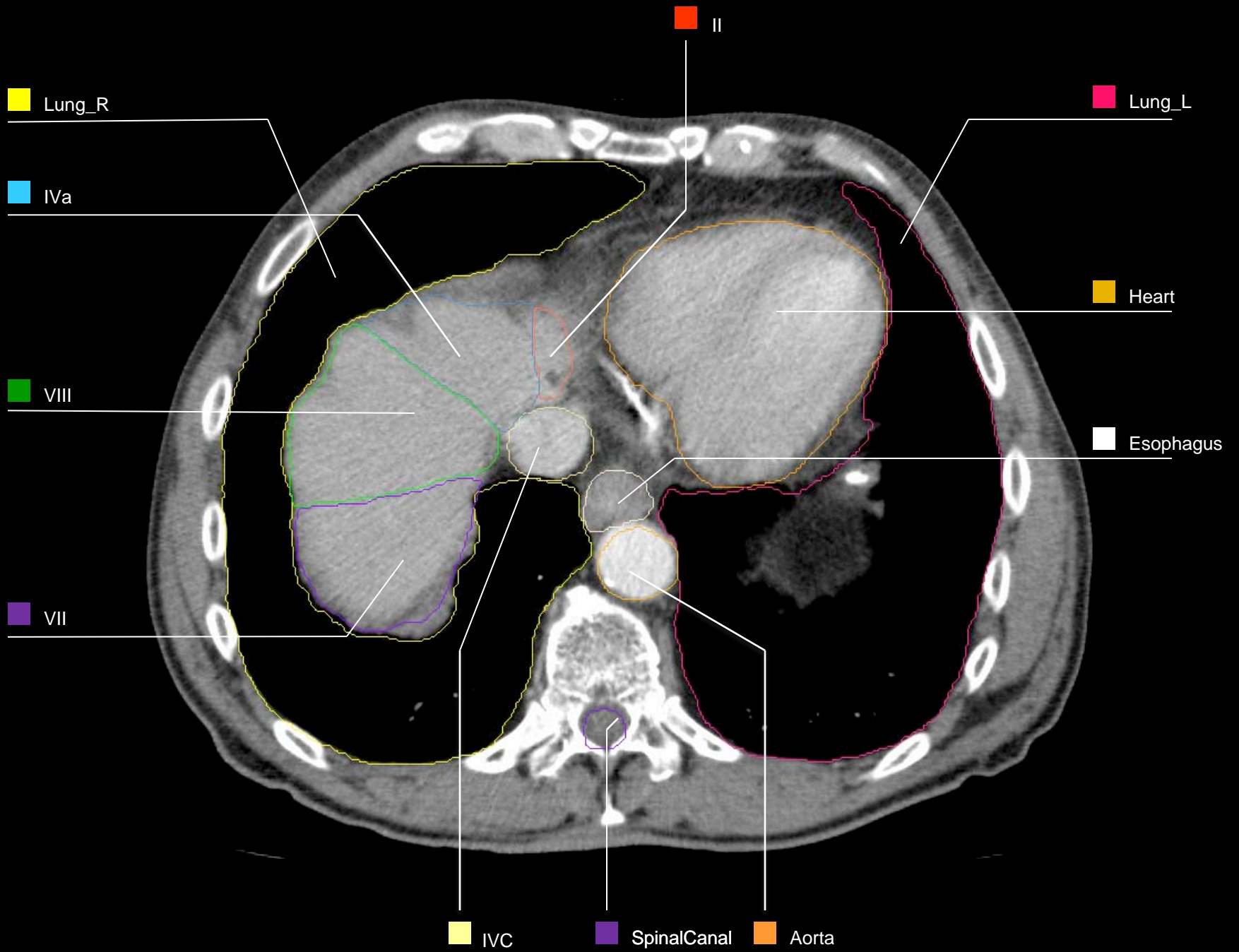
Aorta

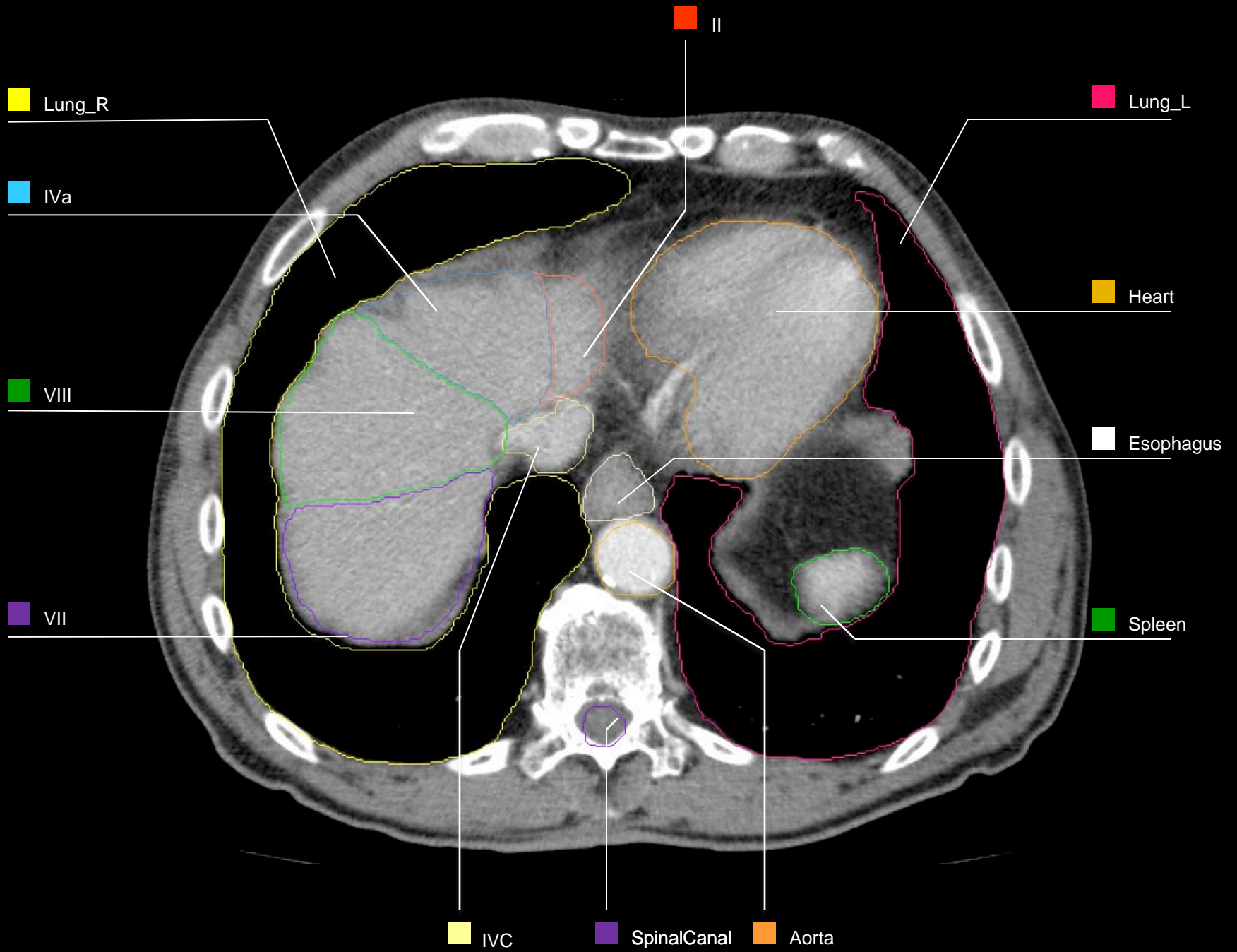


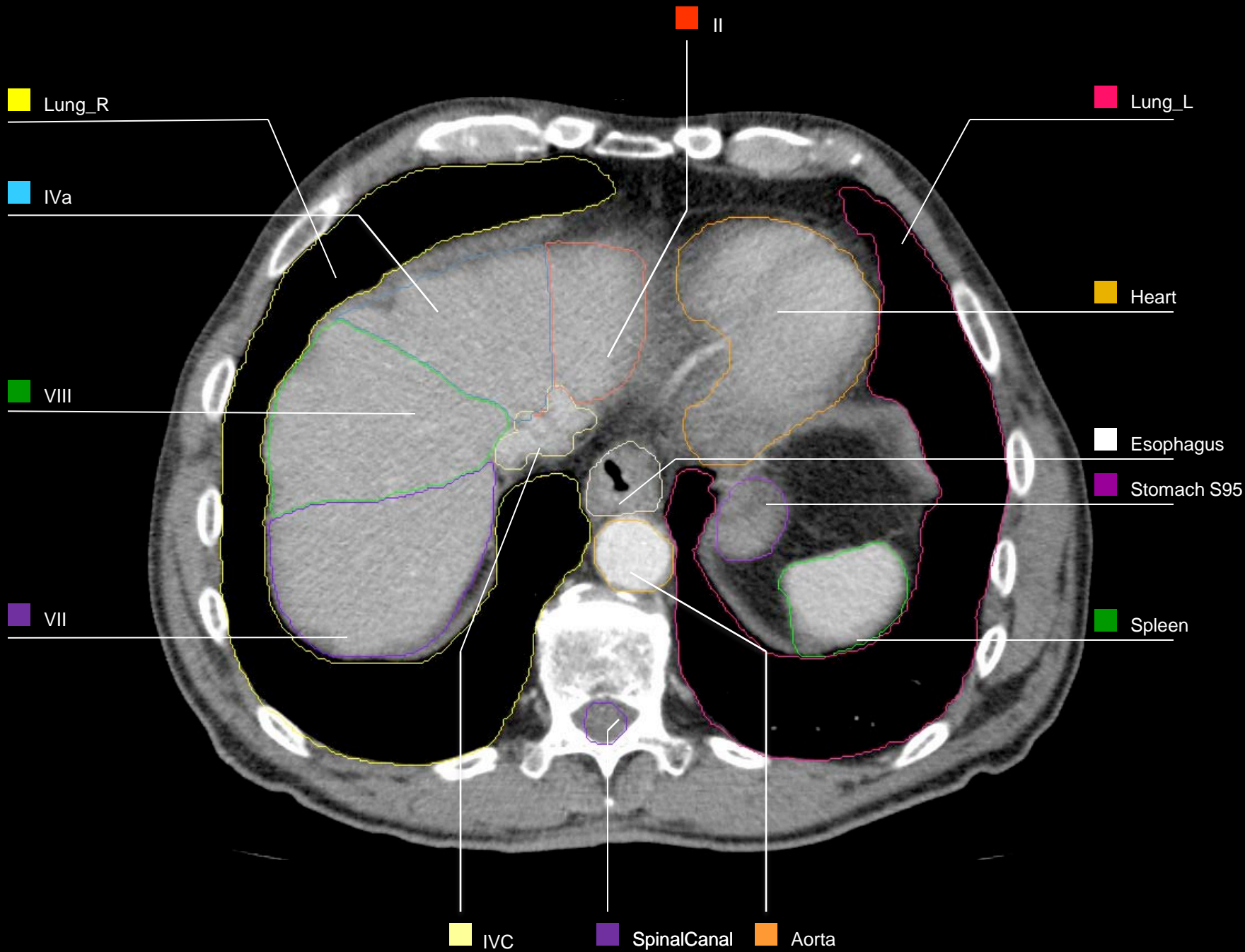


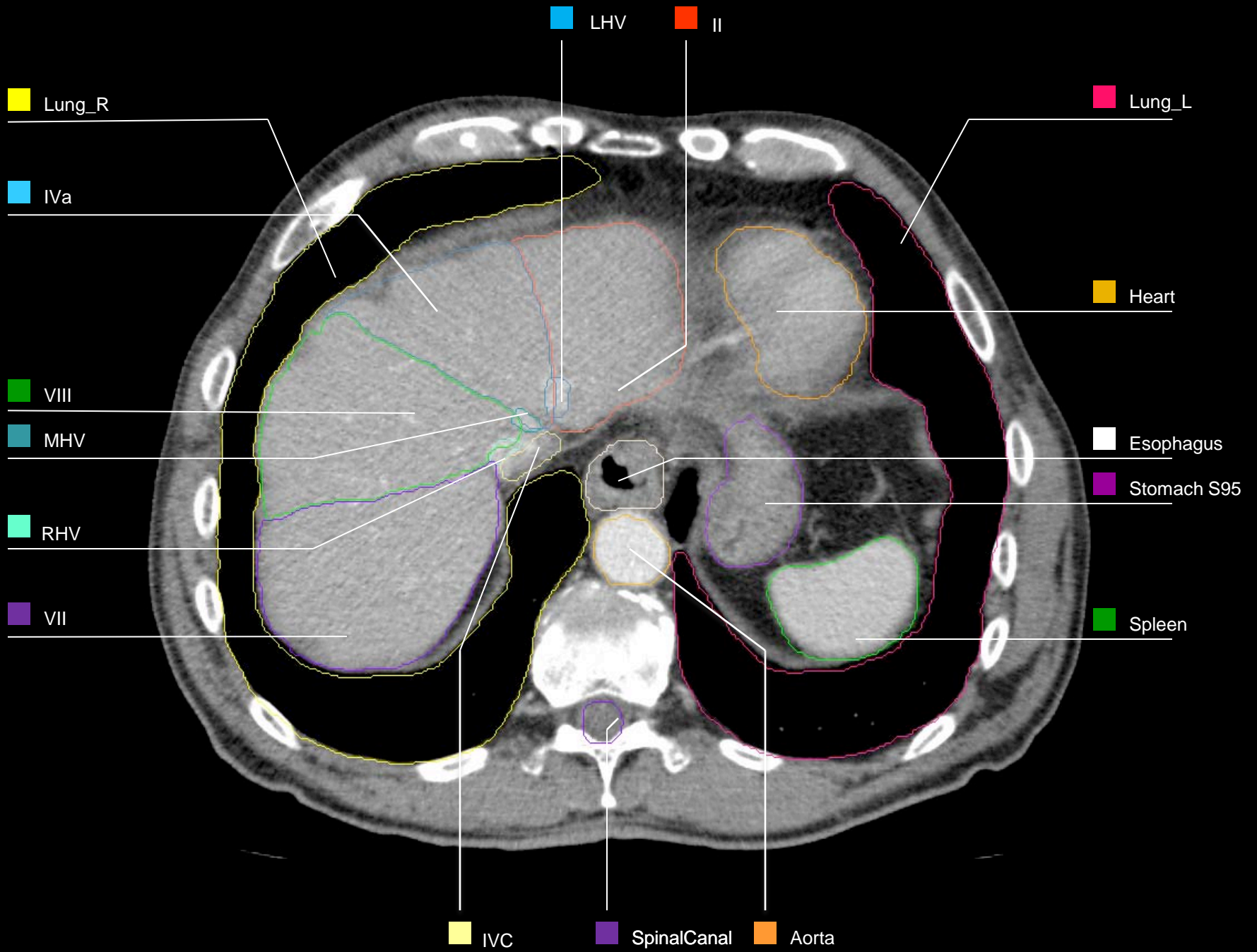


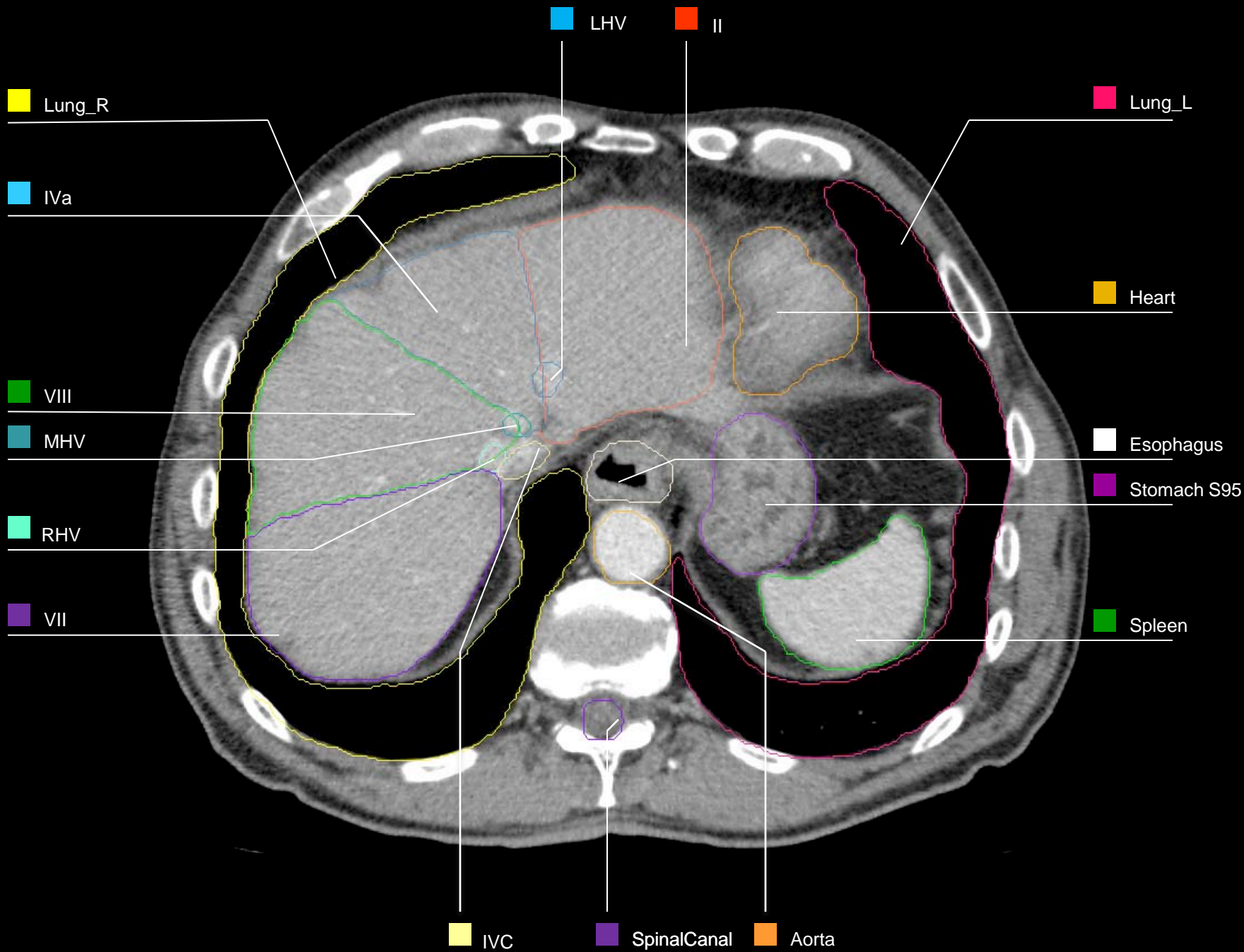


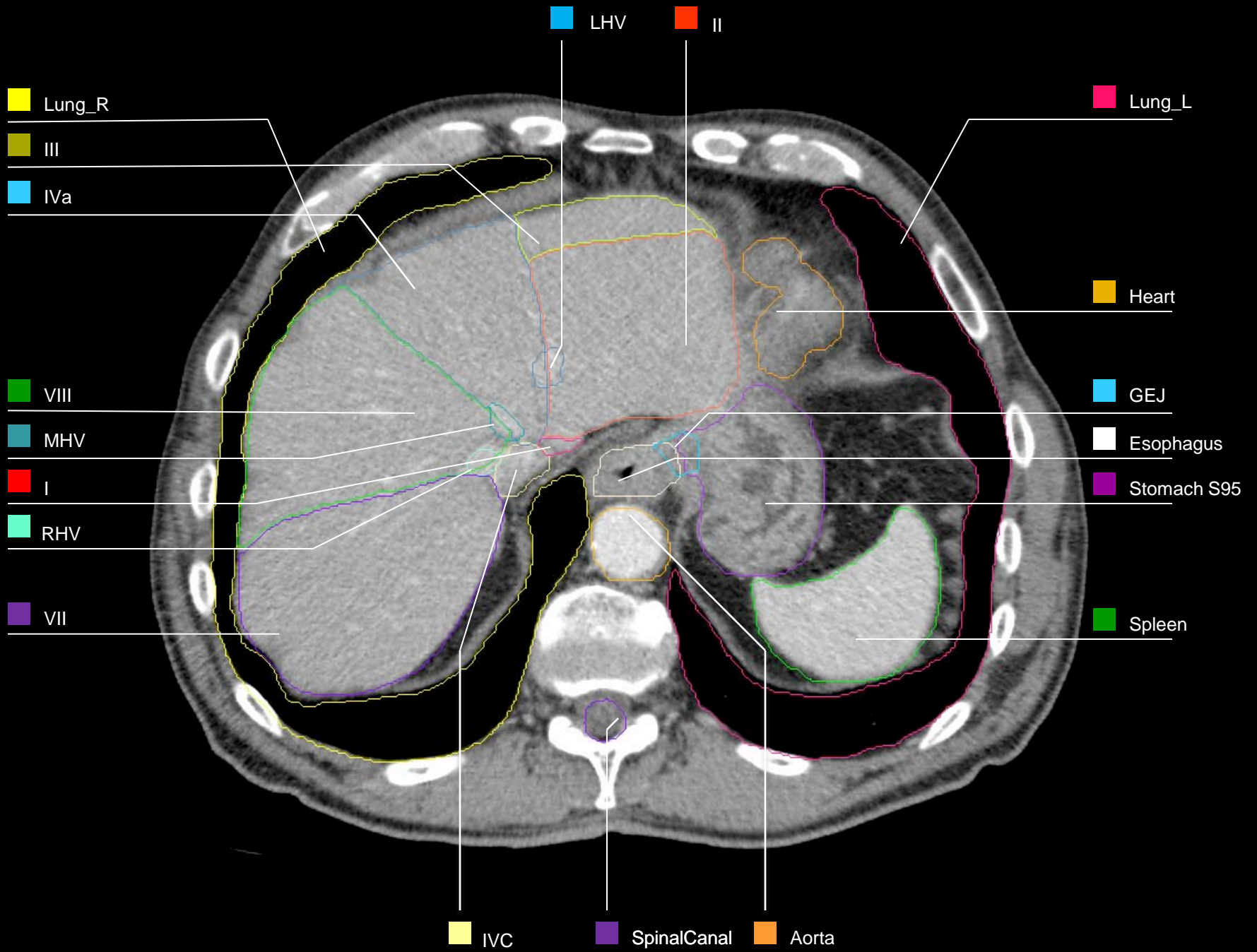


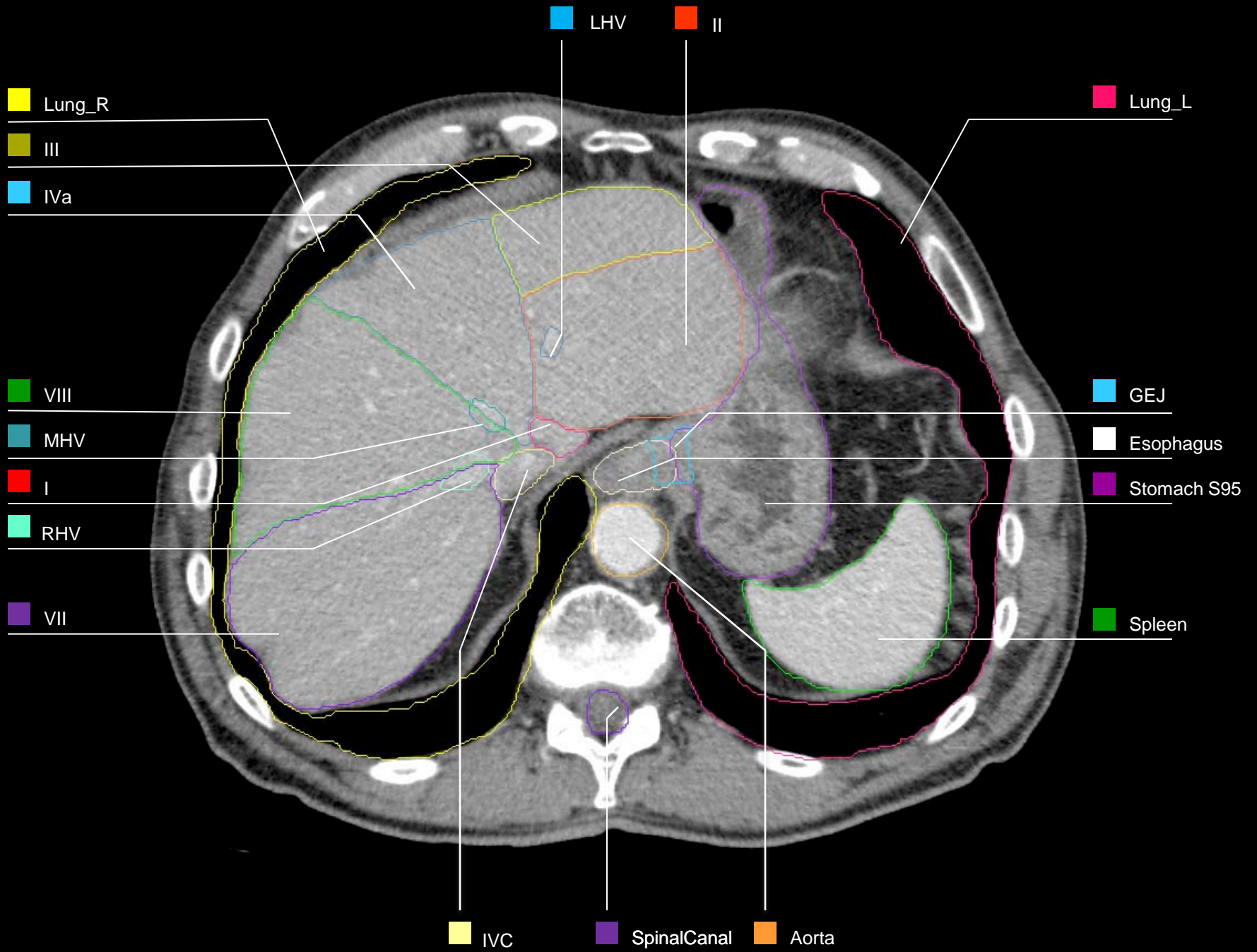


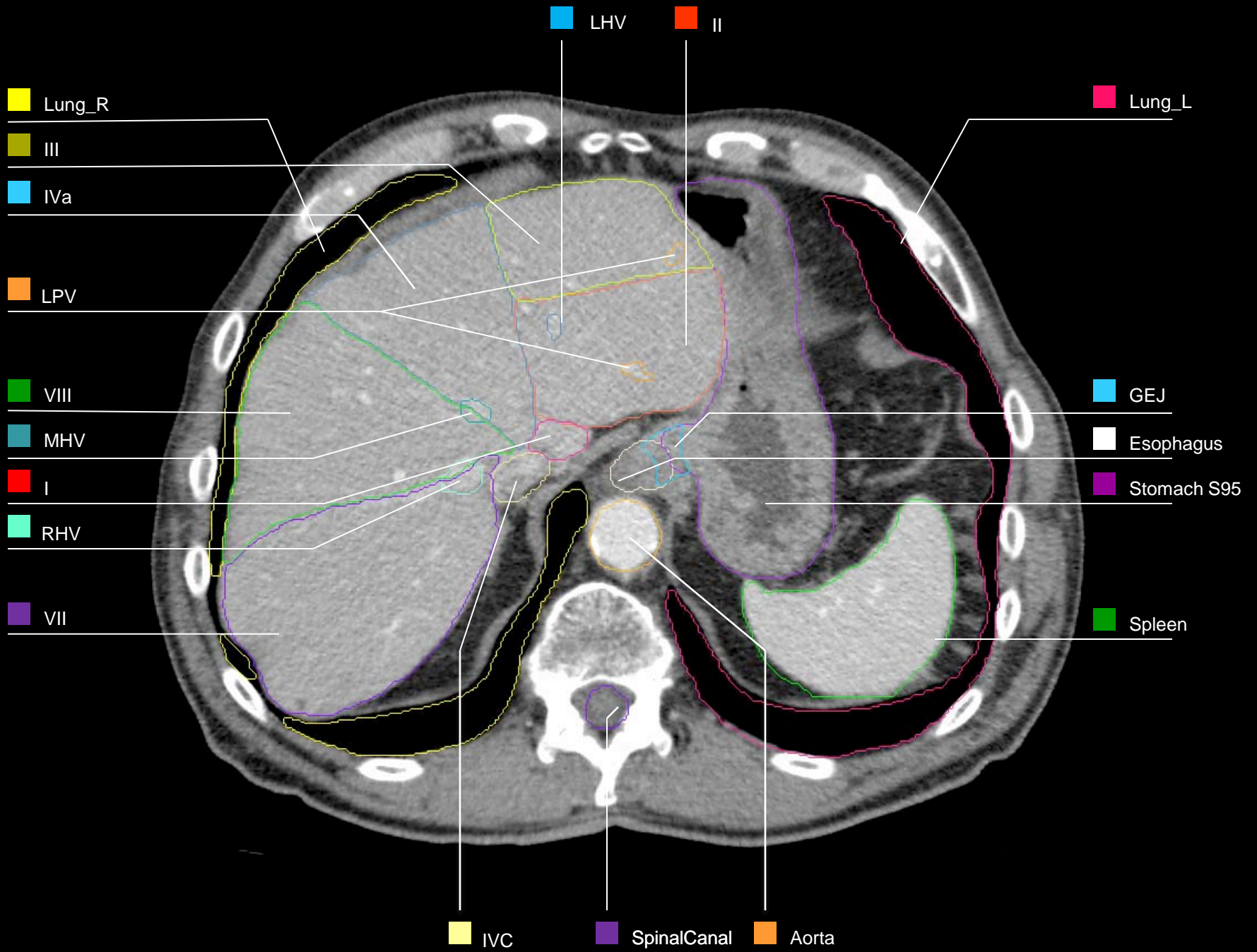


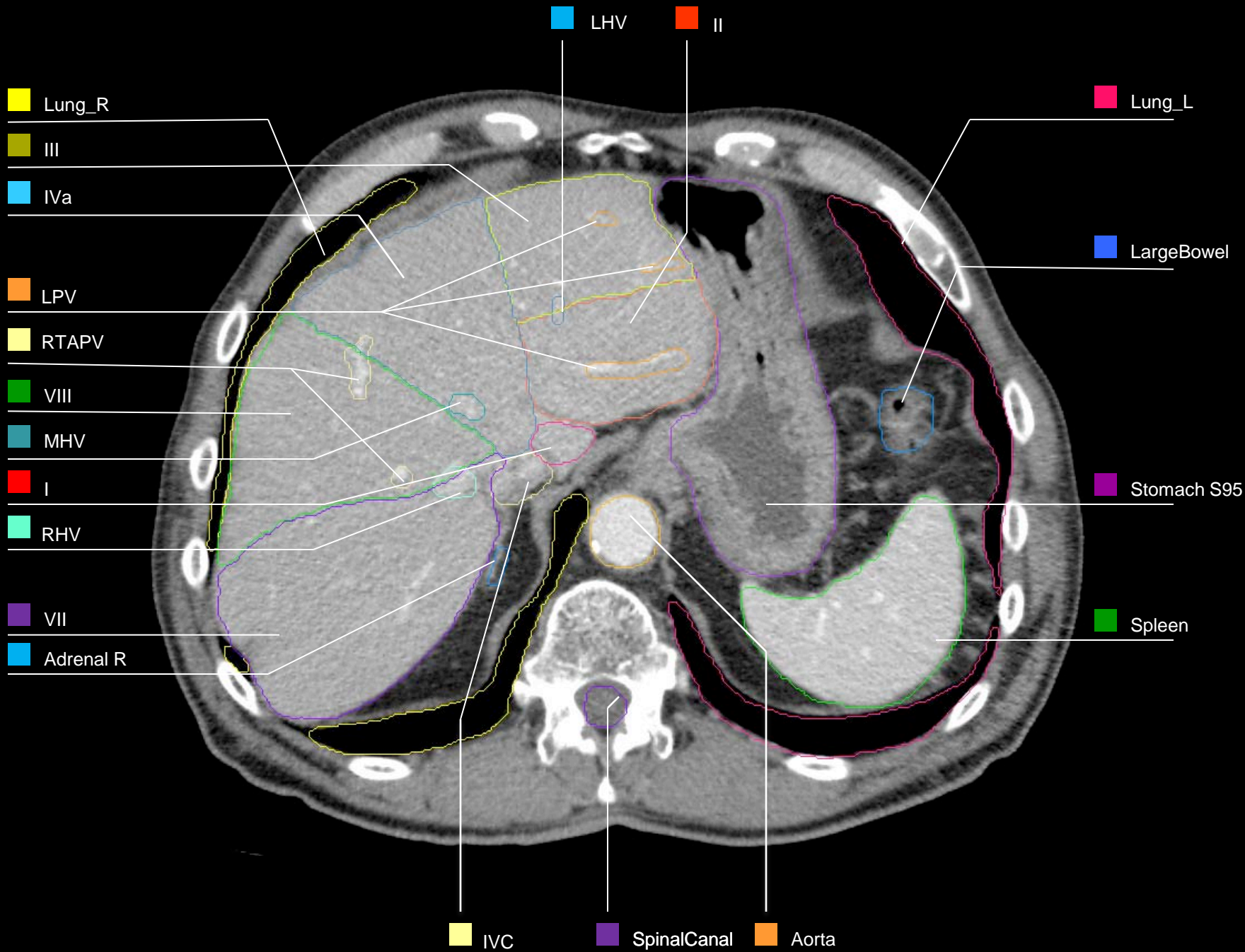


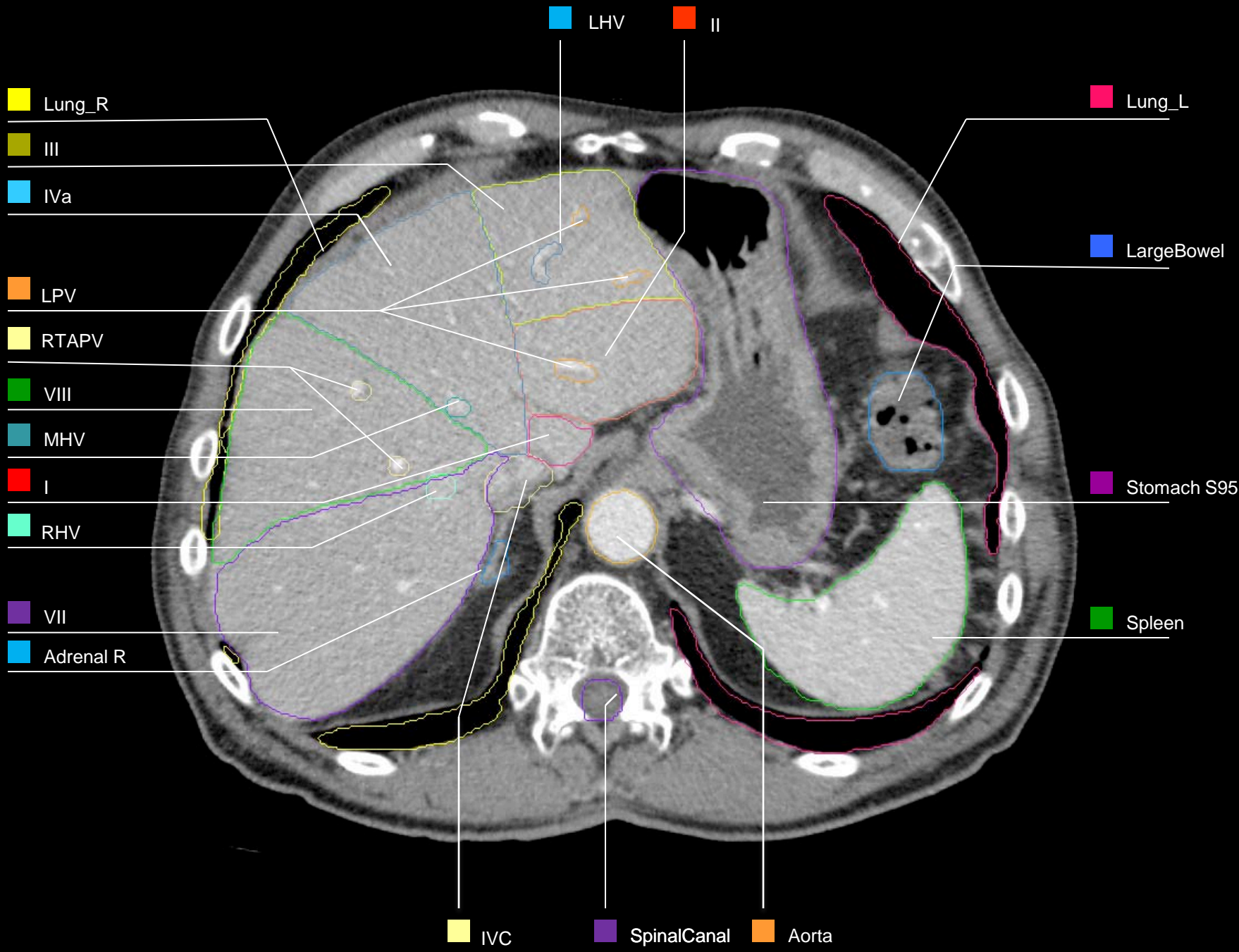


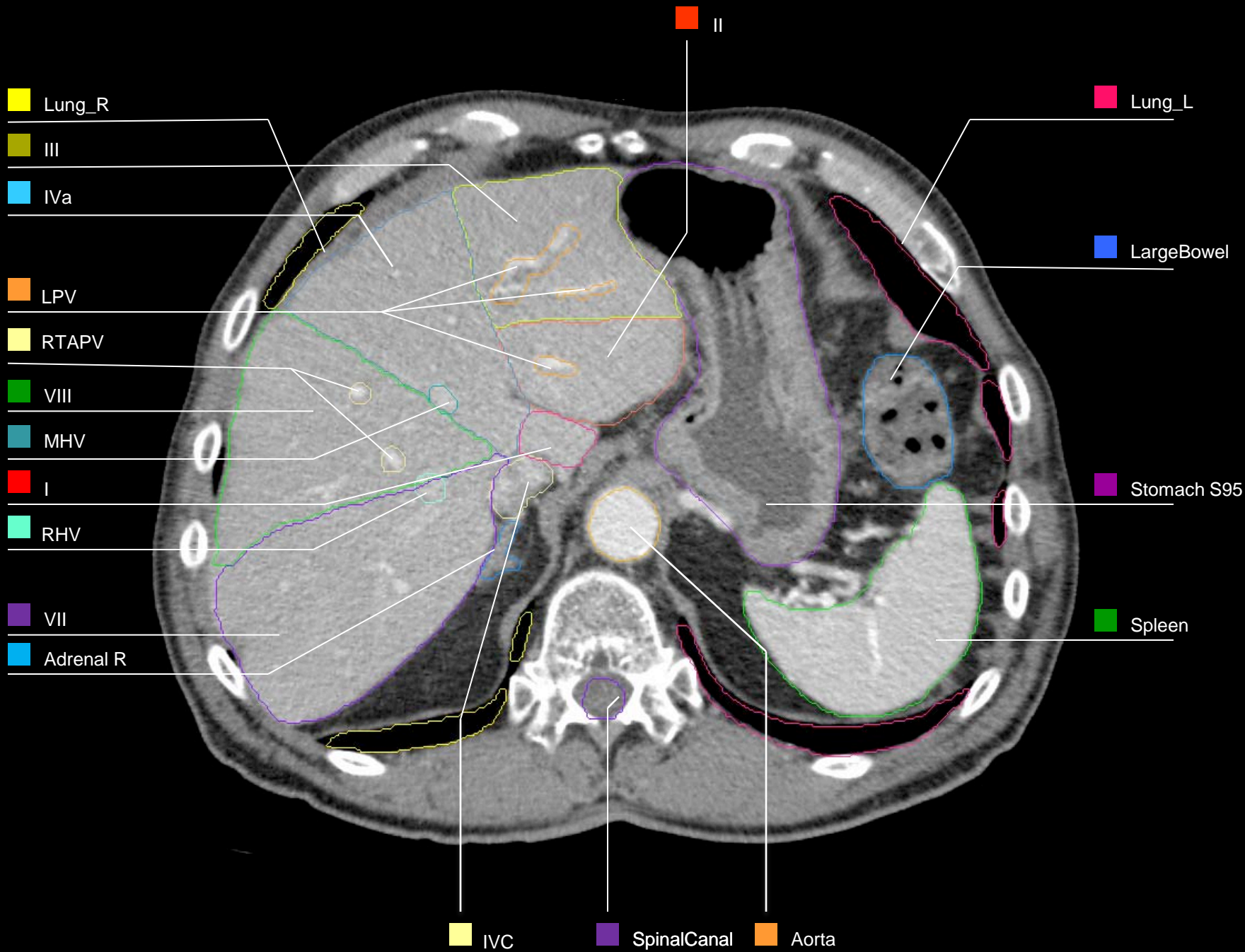


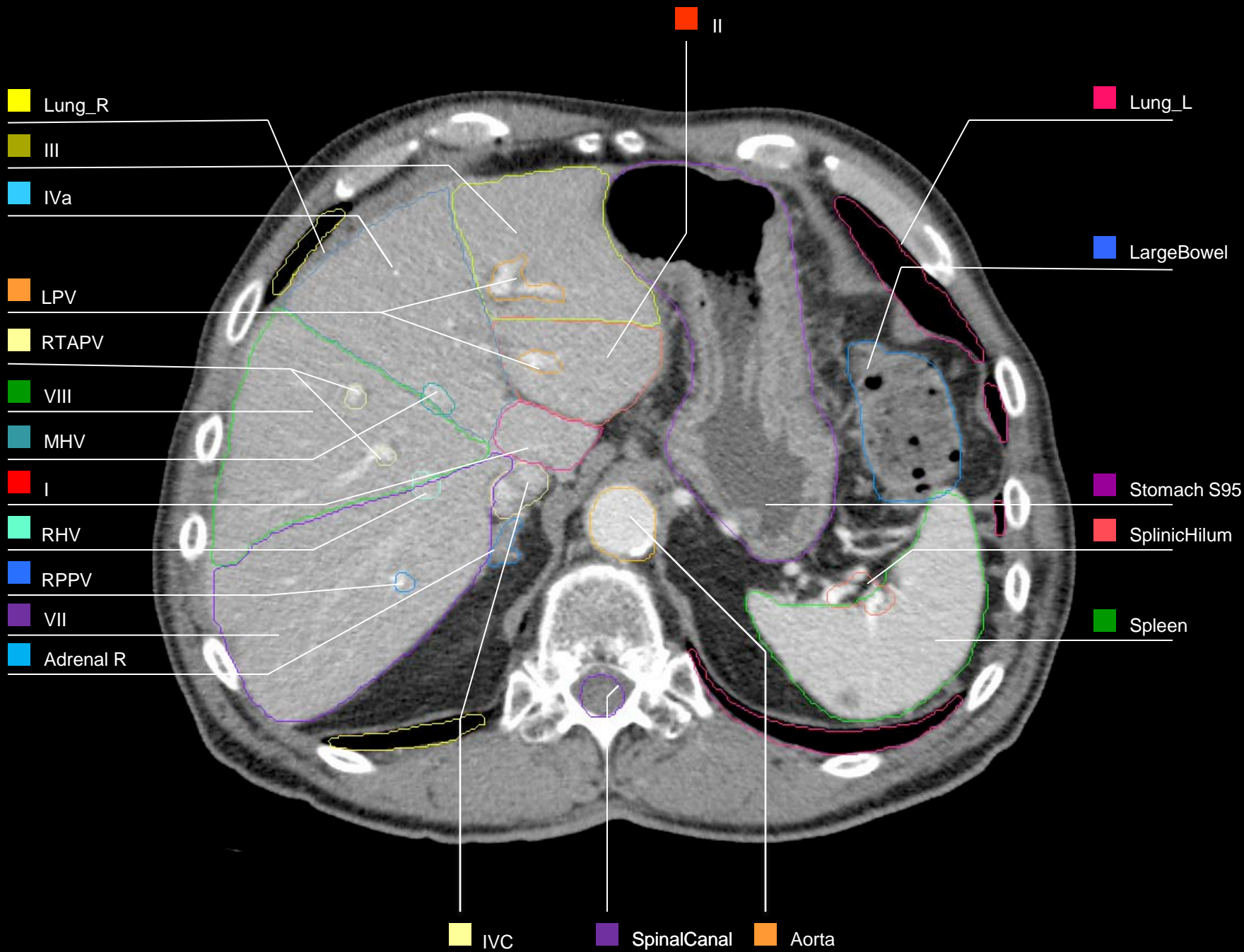


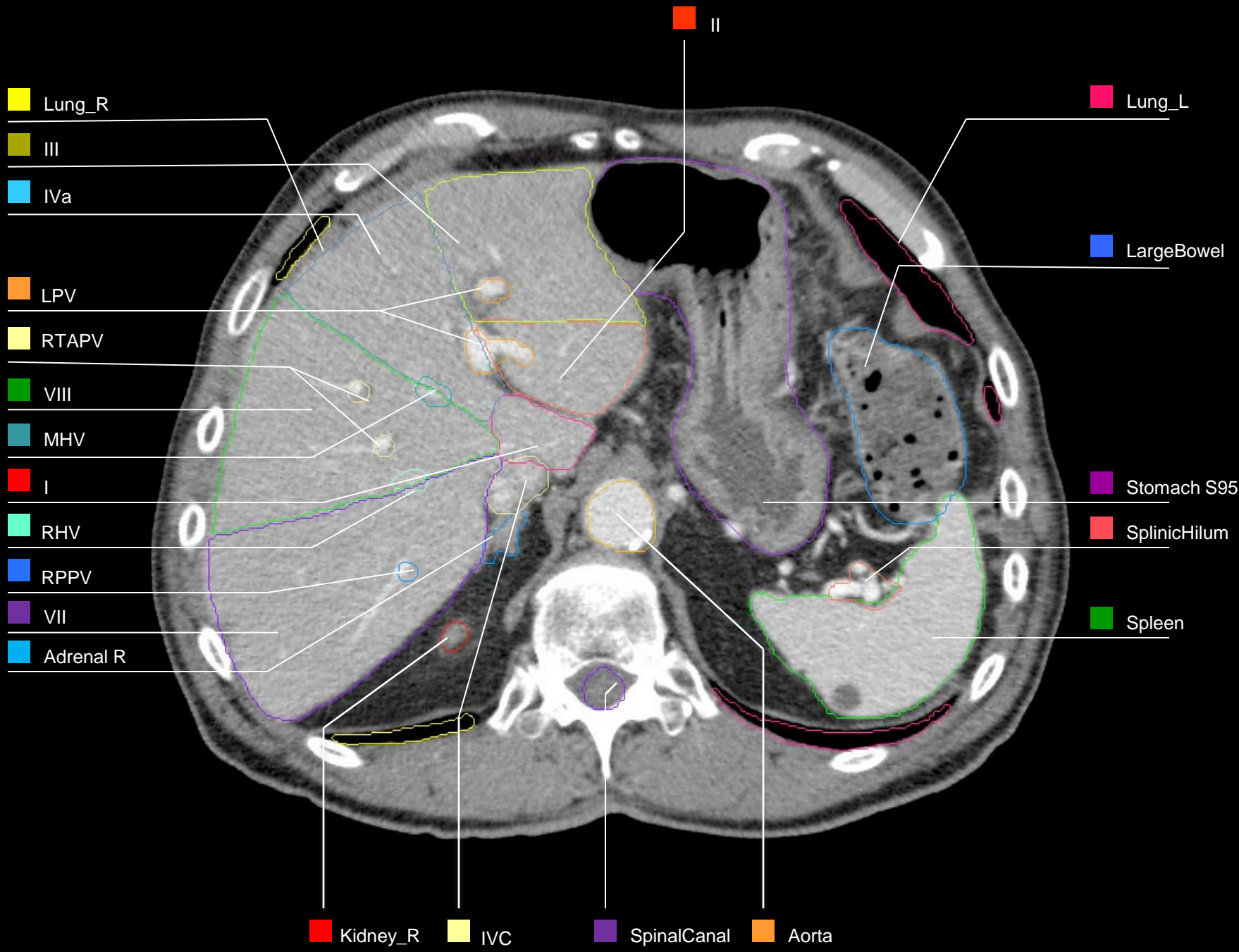








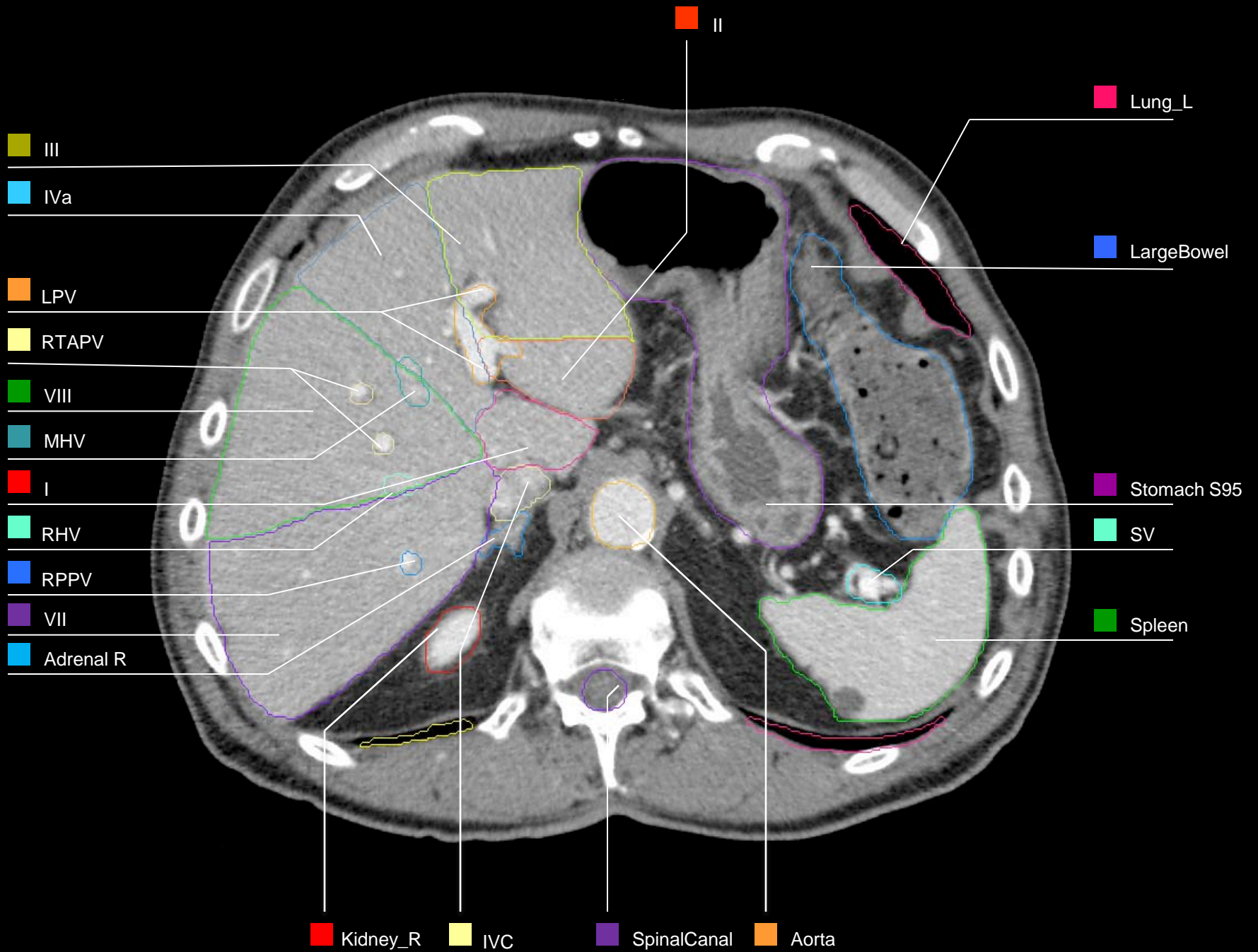


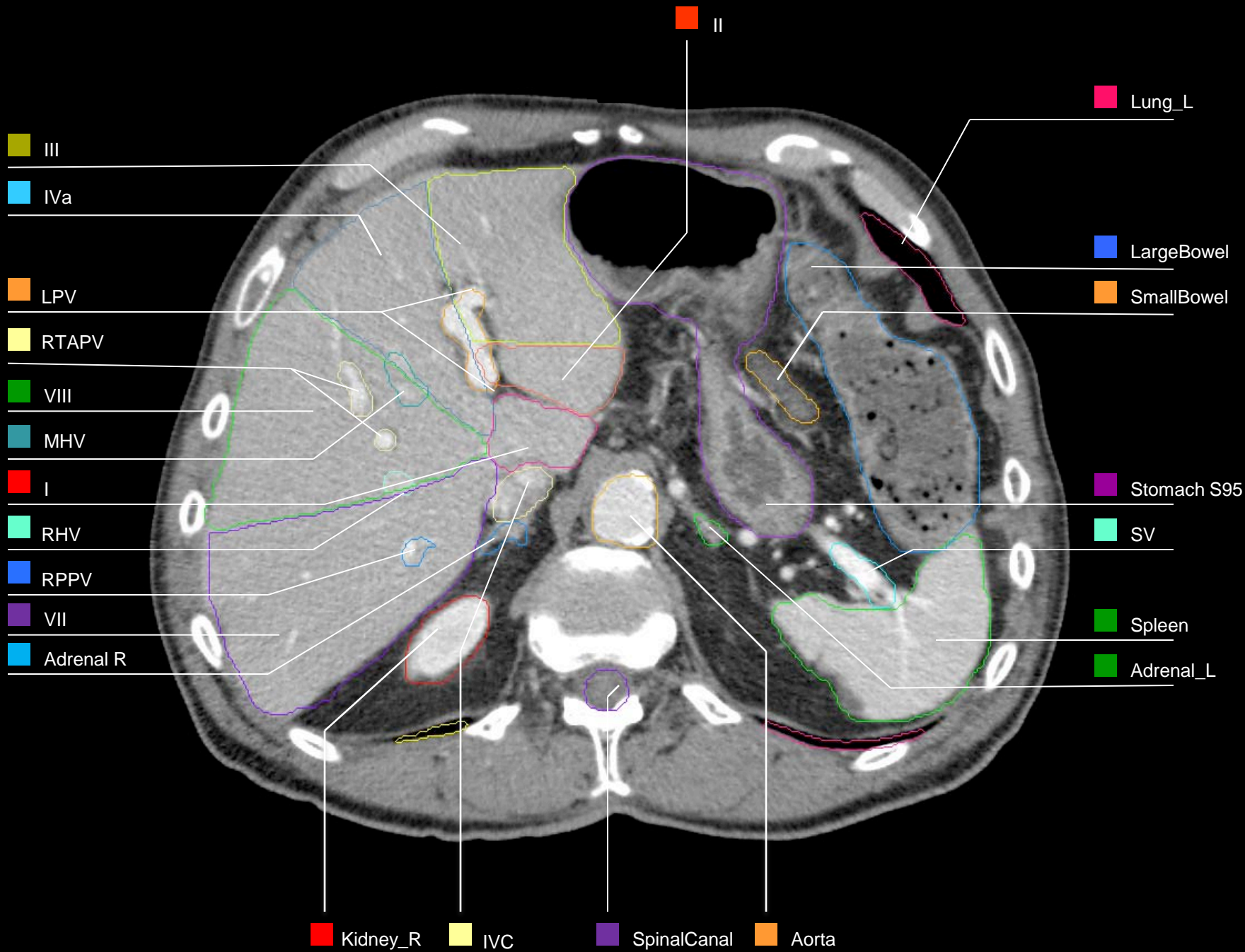


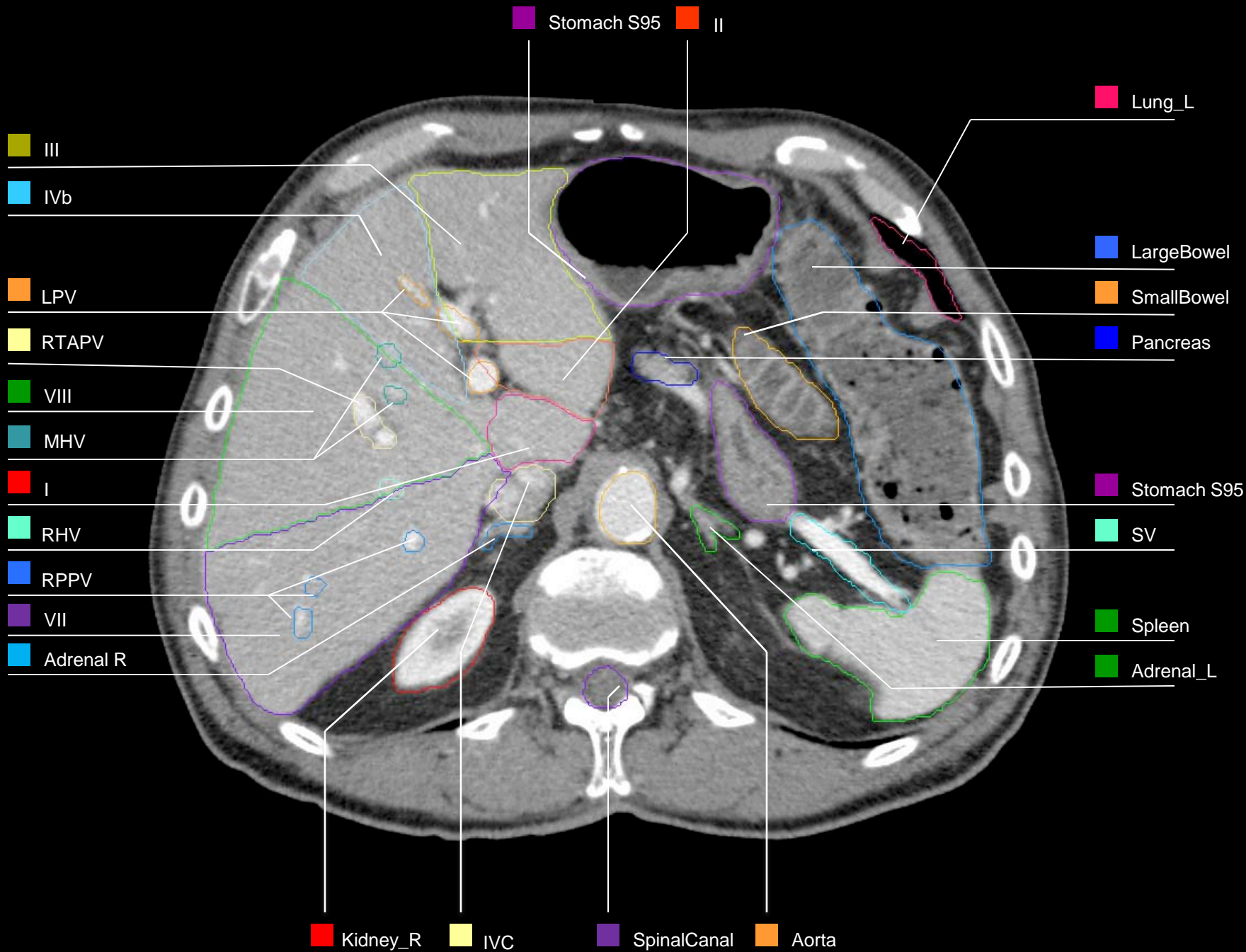
- Lung_R
- III
- IVa
- LPV
- RTAPV
- VIII
- MHV
- I
- RHV
- RPPV
- VII
- Adrenal R

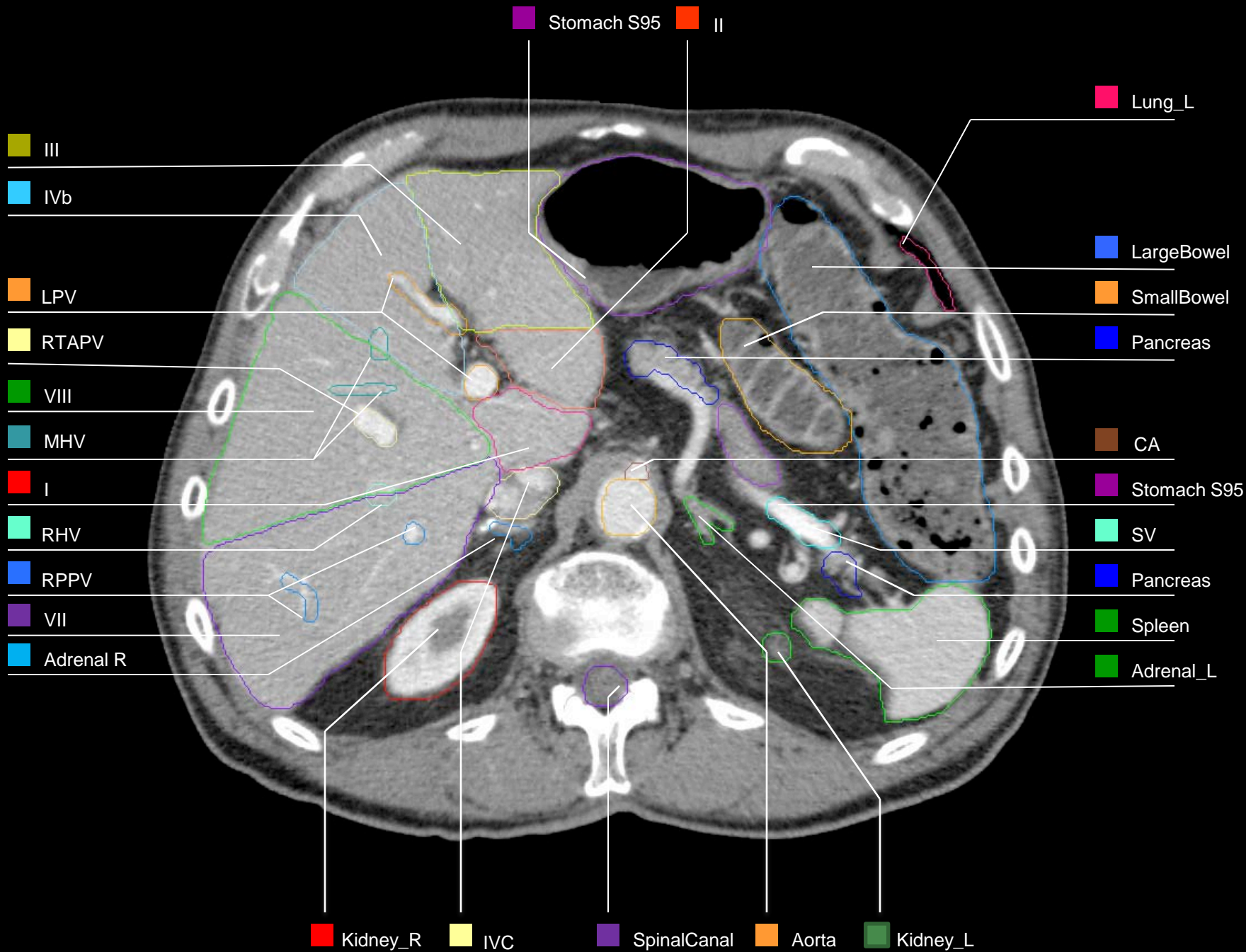
- Lung_L
- LargeBowel
- Stomach S95
- SplenicHilum
- Spleen

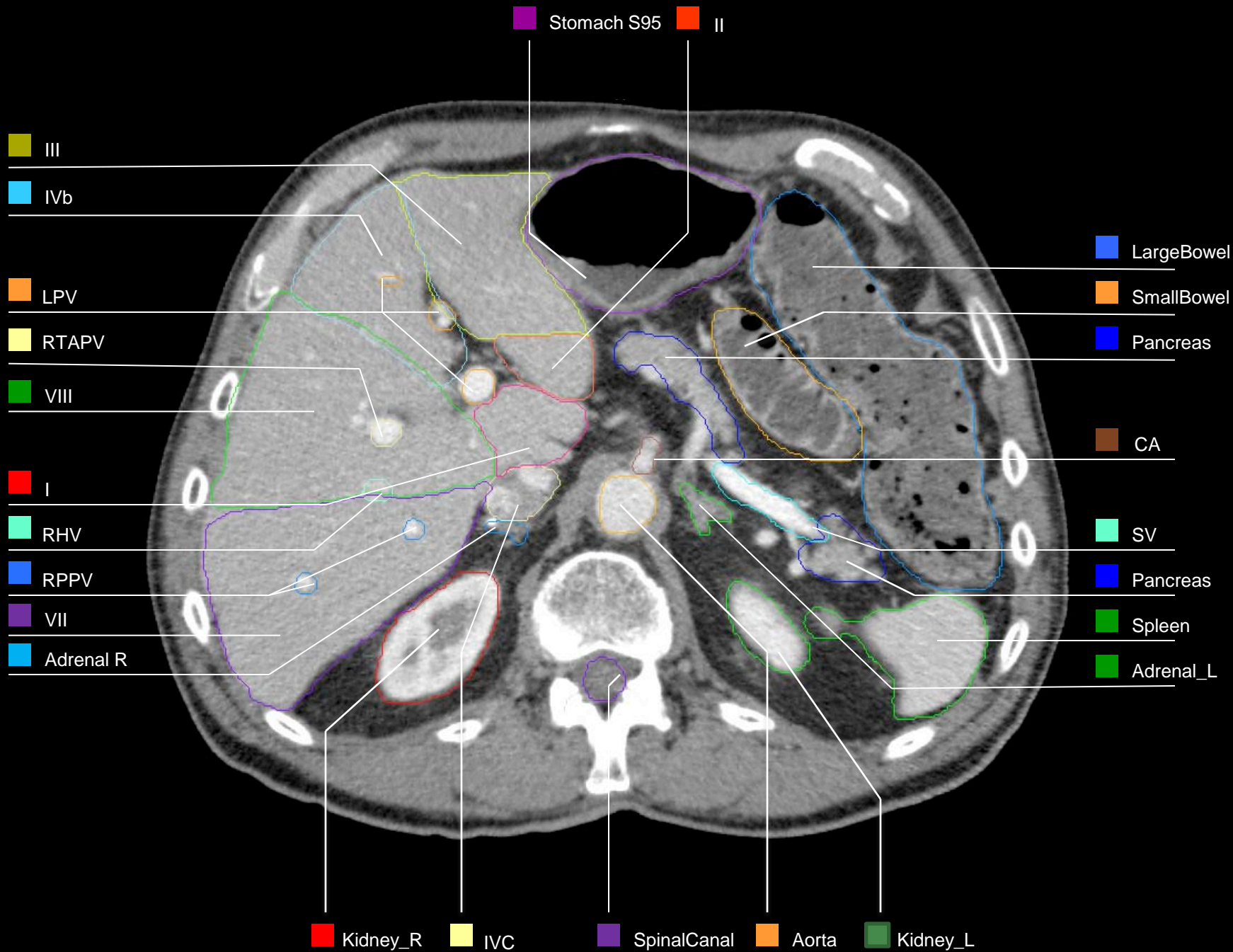
- Kidney_R
- IVC
- SpinalCanal
- Aorta

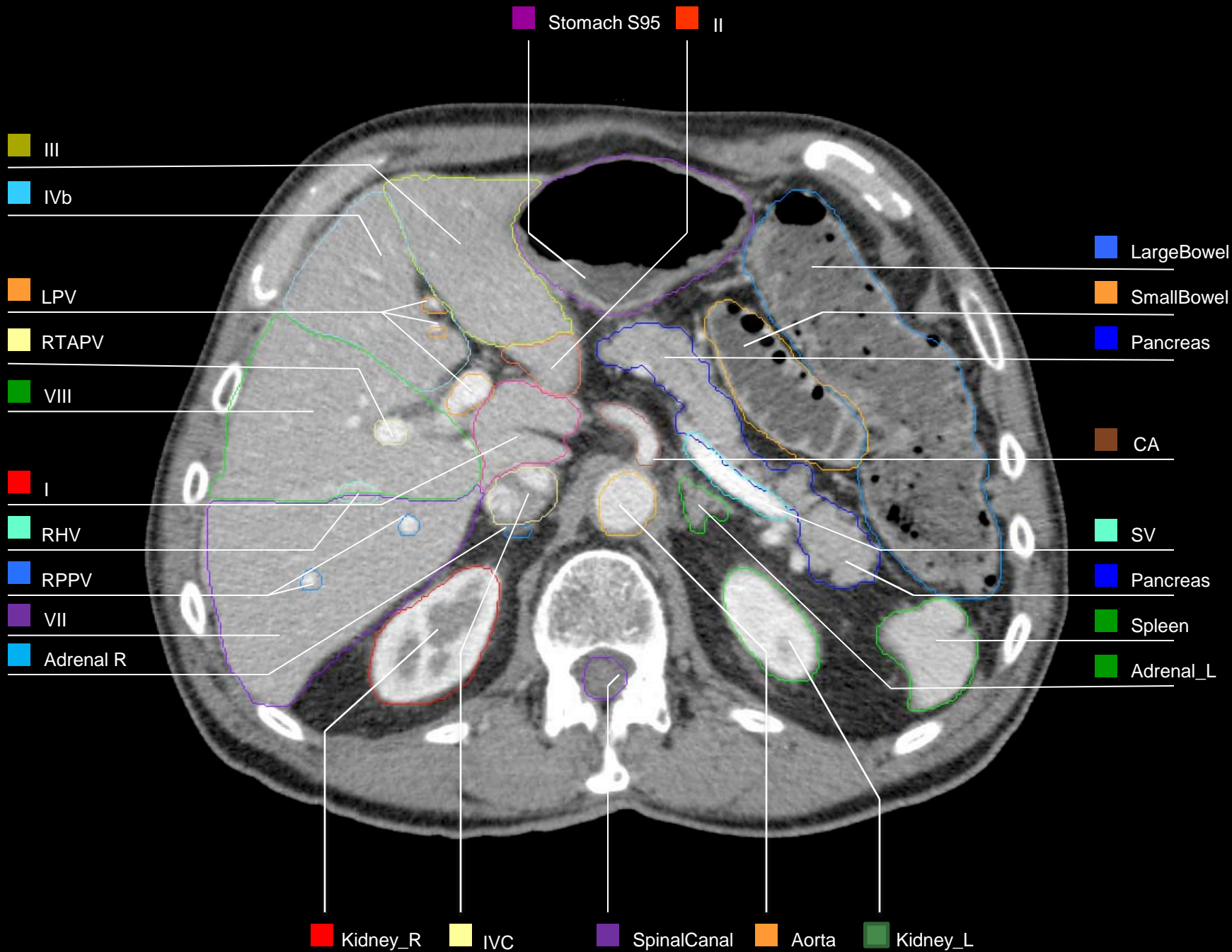


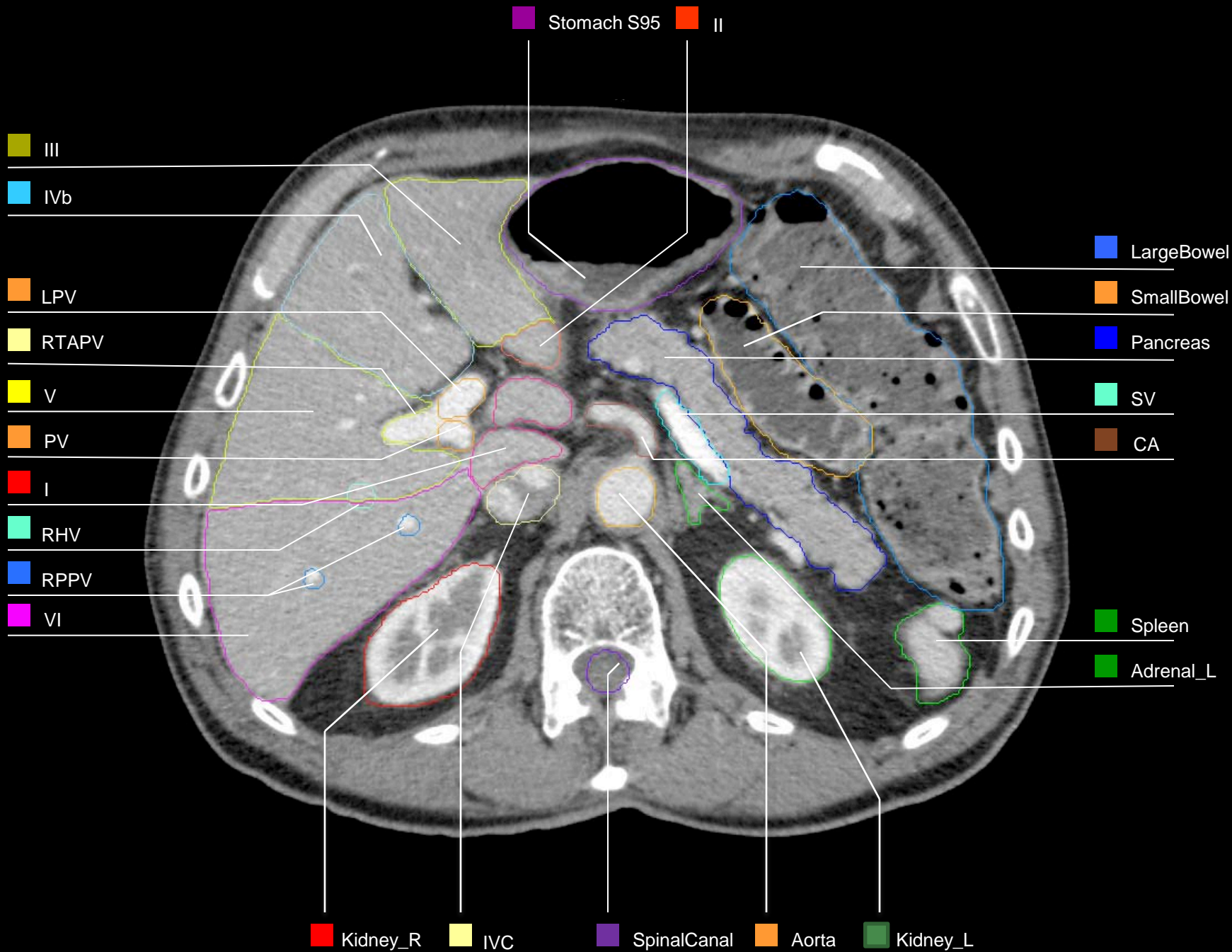












Stomach S95 CHA

III

IVb

LPV

RTAPV

V

PV

I

RHV

RPPV

VI

LargeBowel

SmallBowel

Pancreas

SV

CA

SMA

Spleen

Adrenal_L

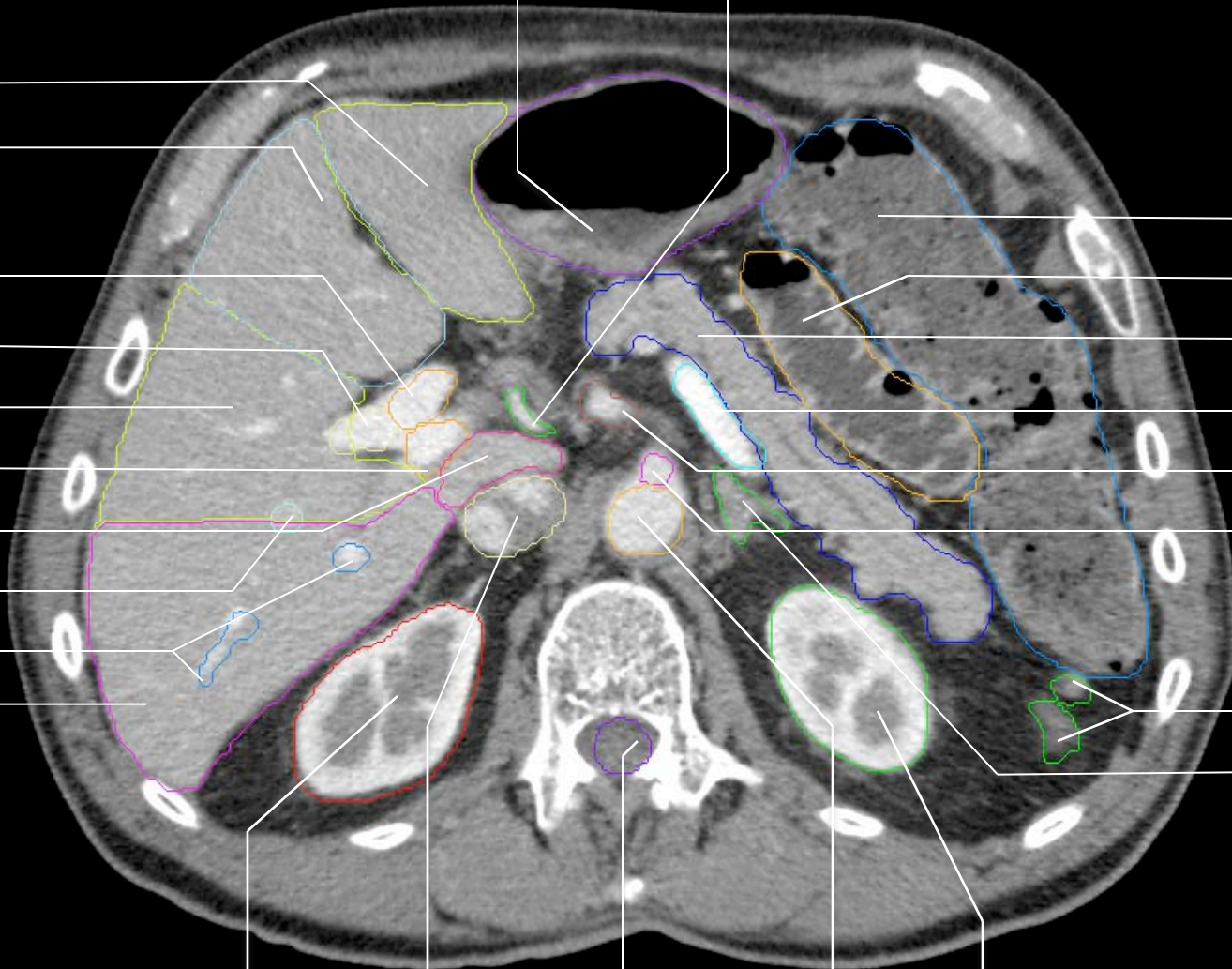
Kidney_R

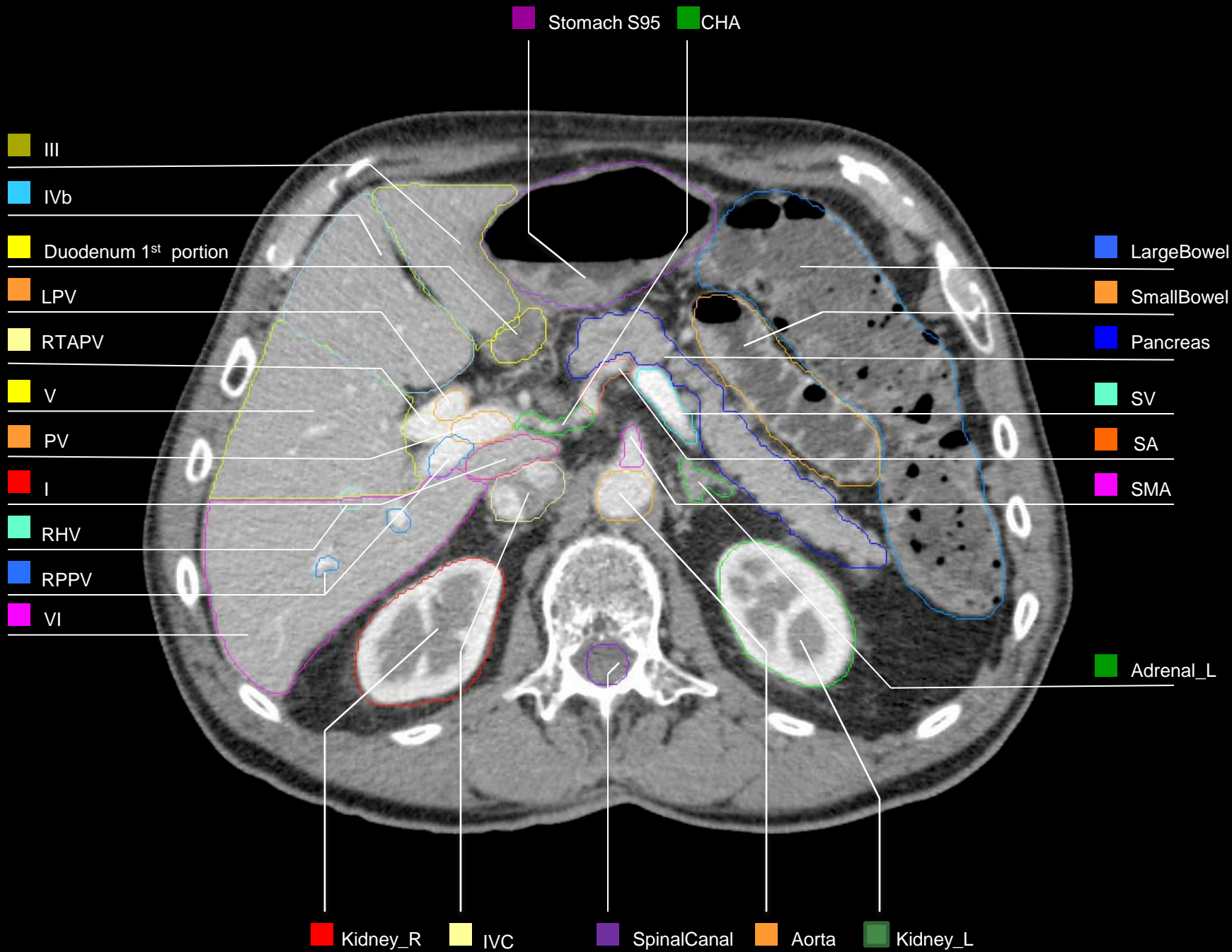
IVC

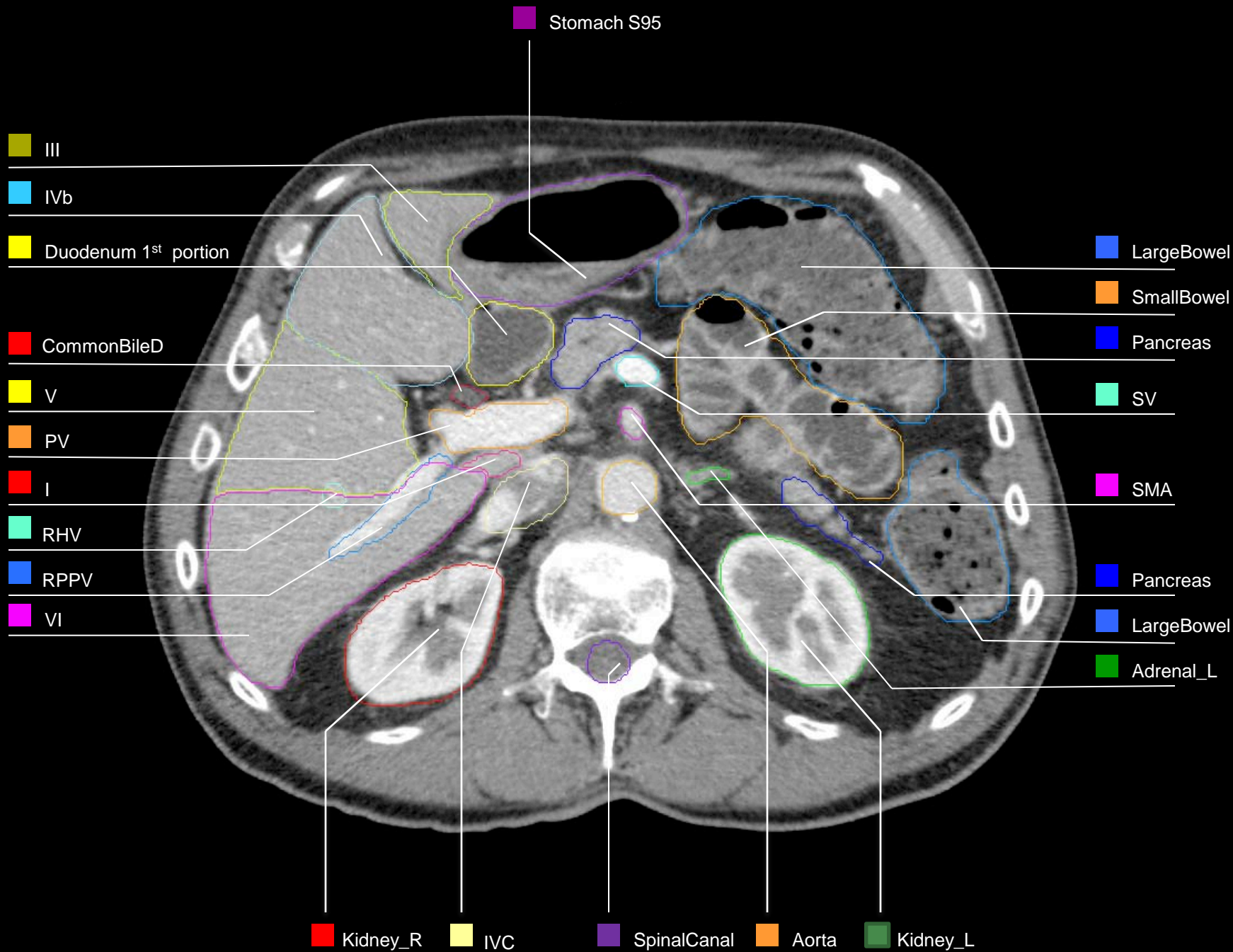
SpinalCanal

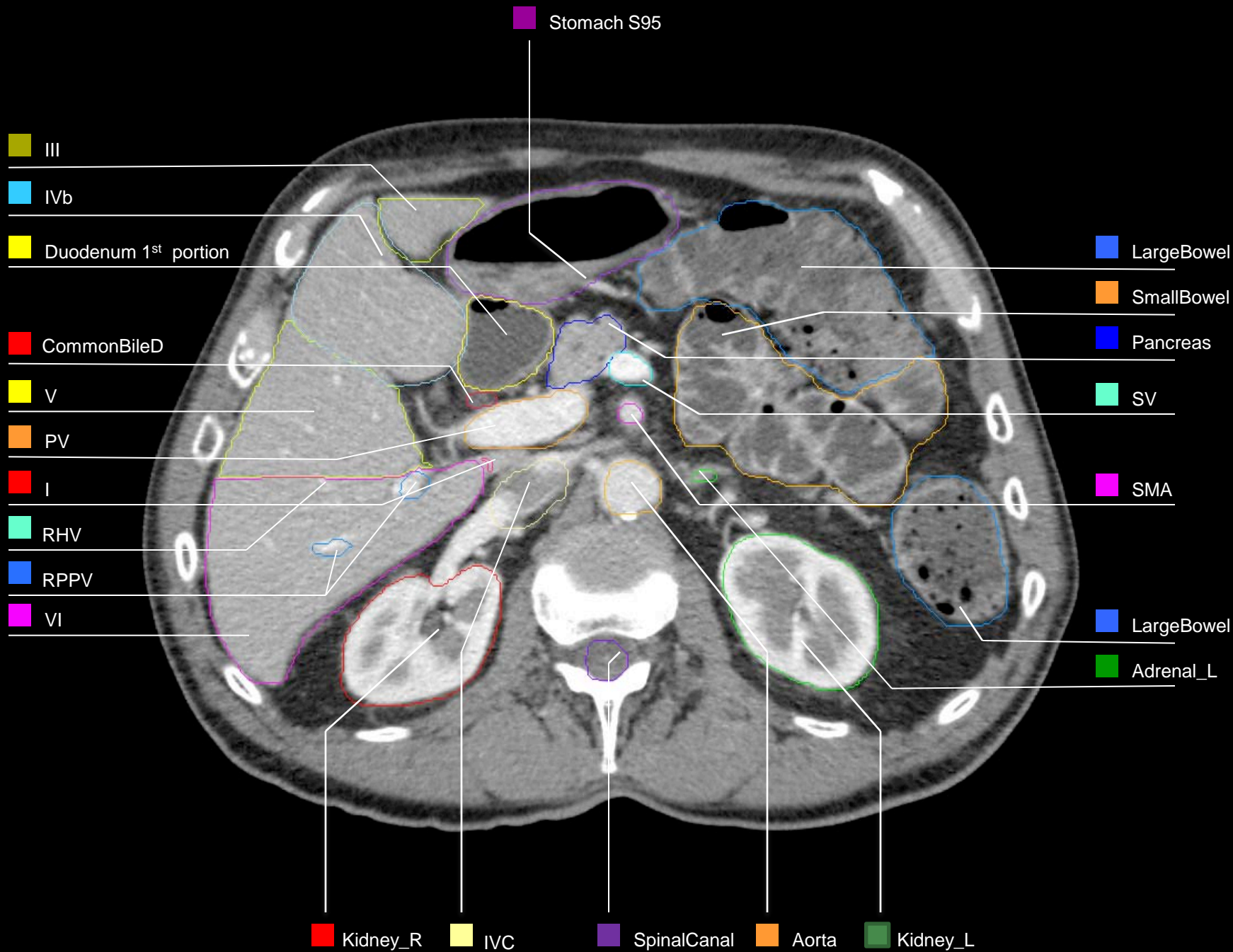
Aorta

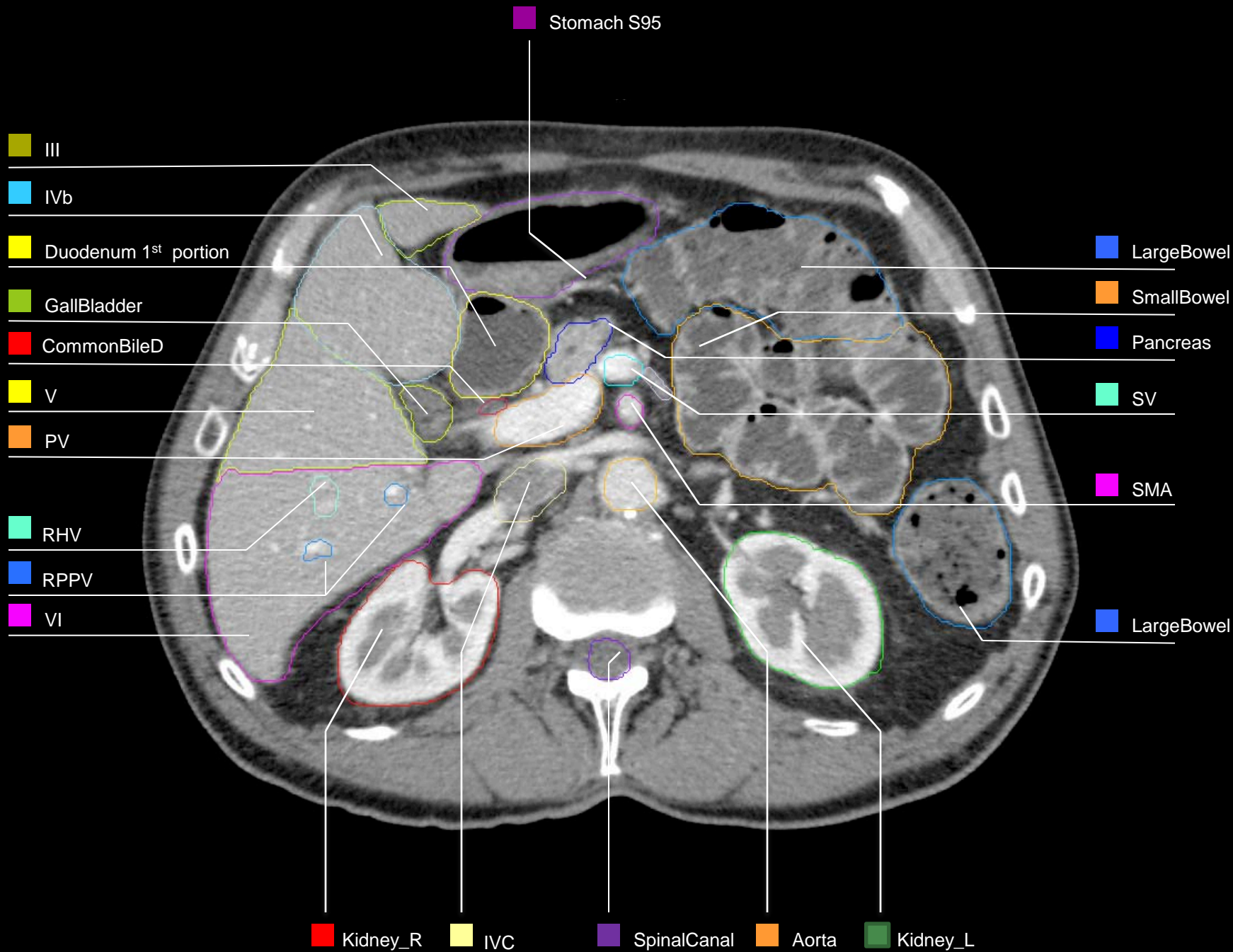
Kidney_L

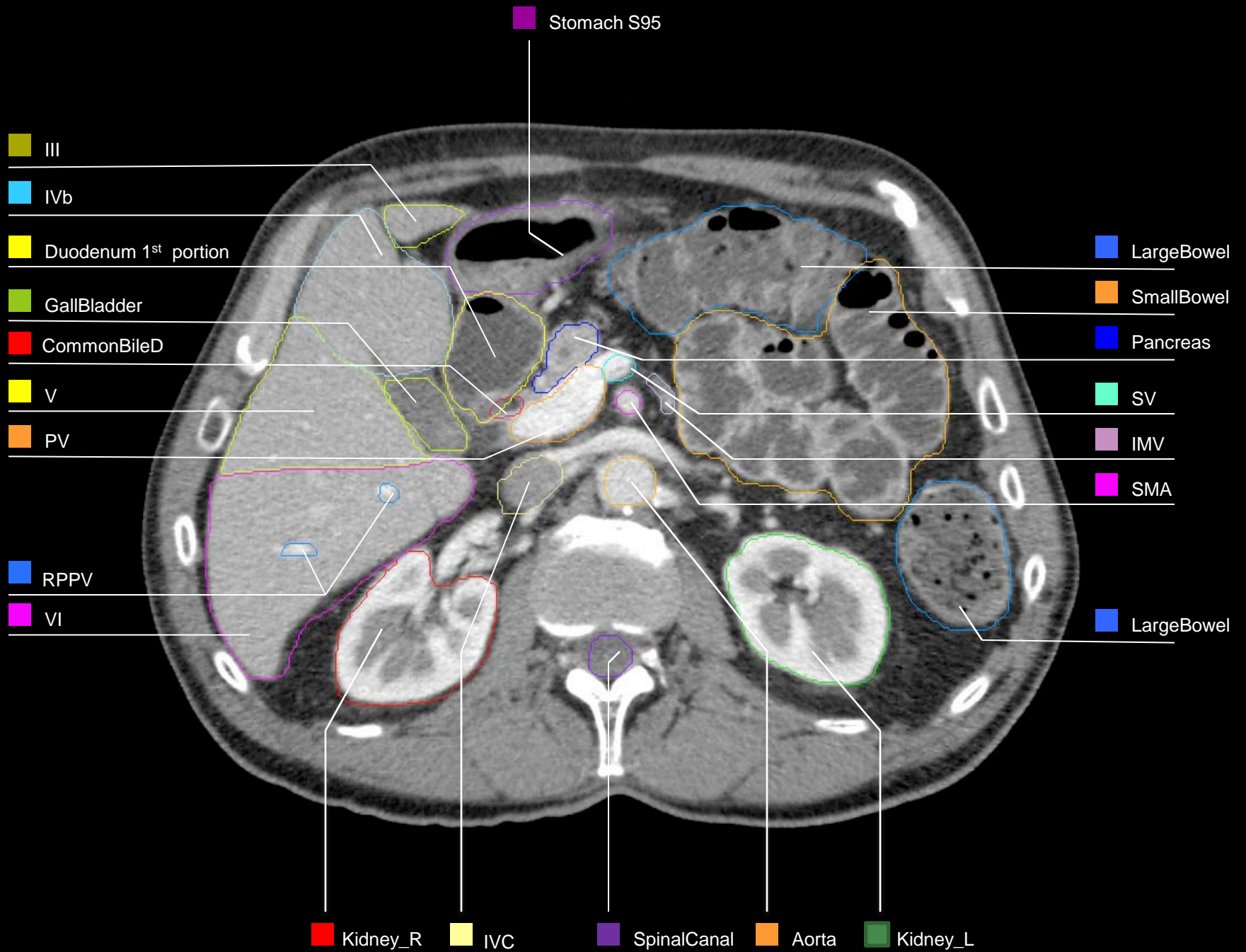


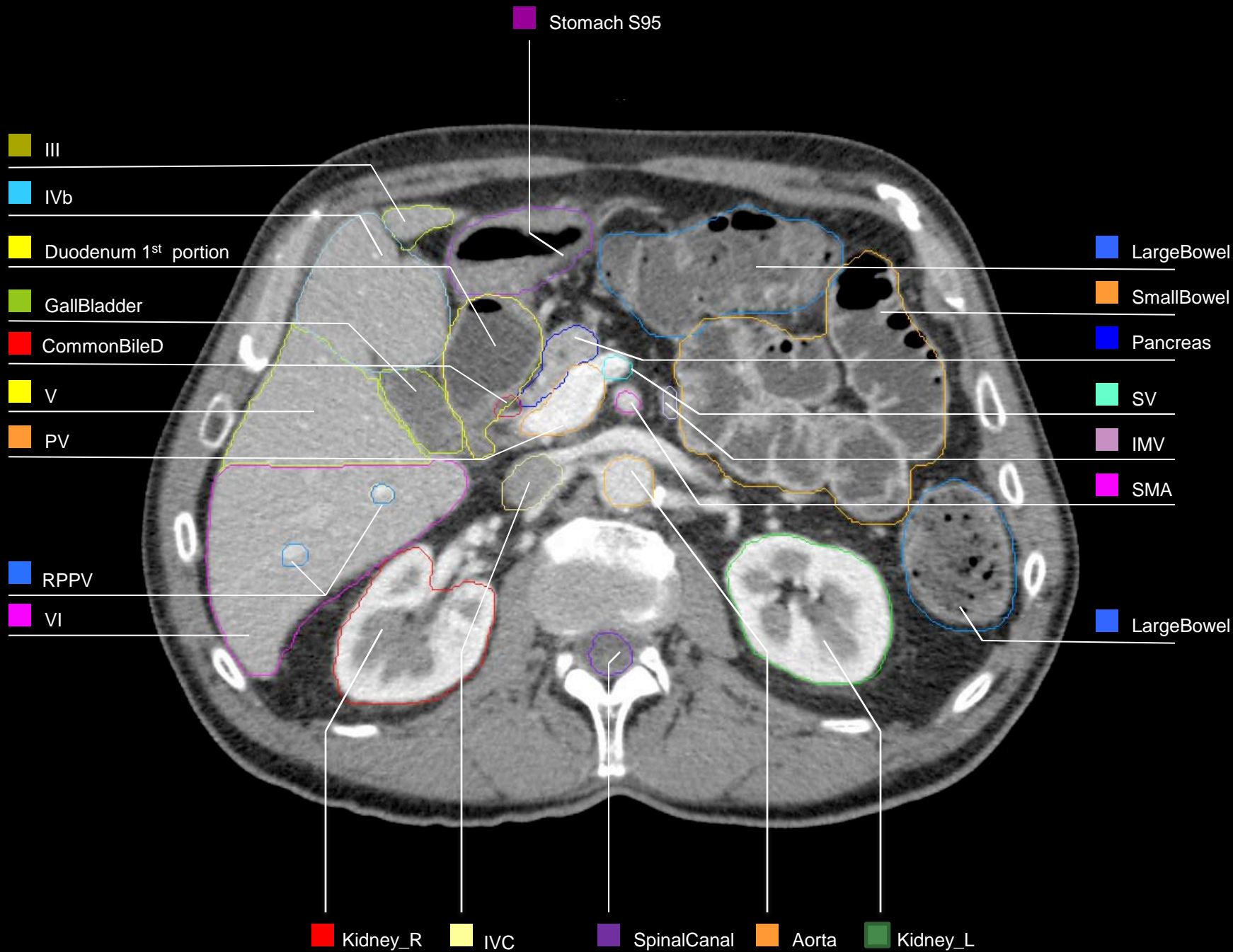


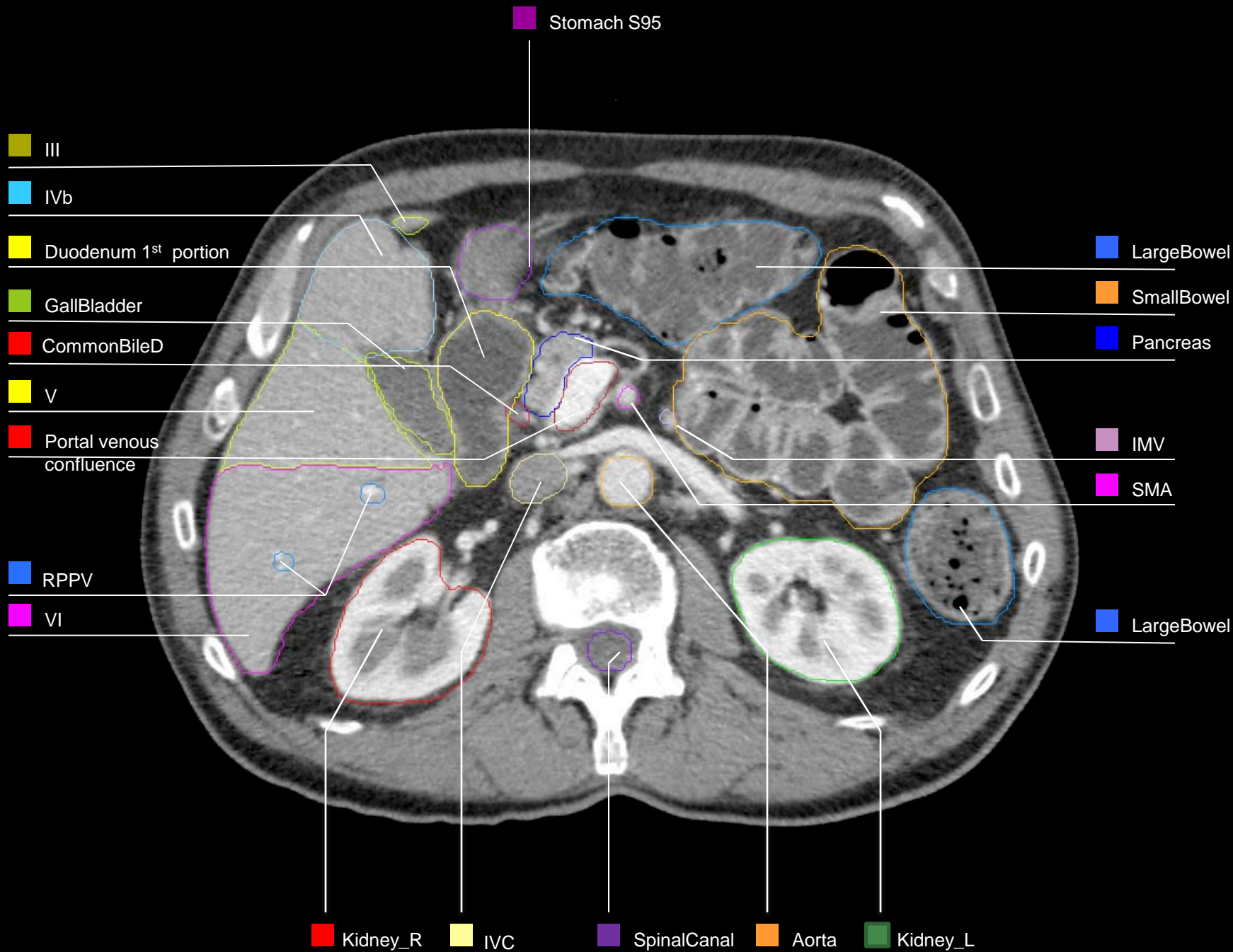


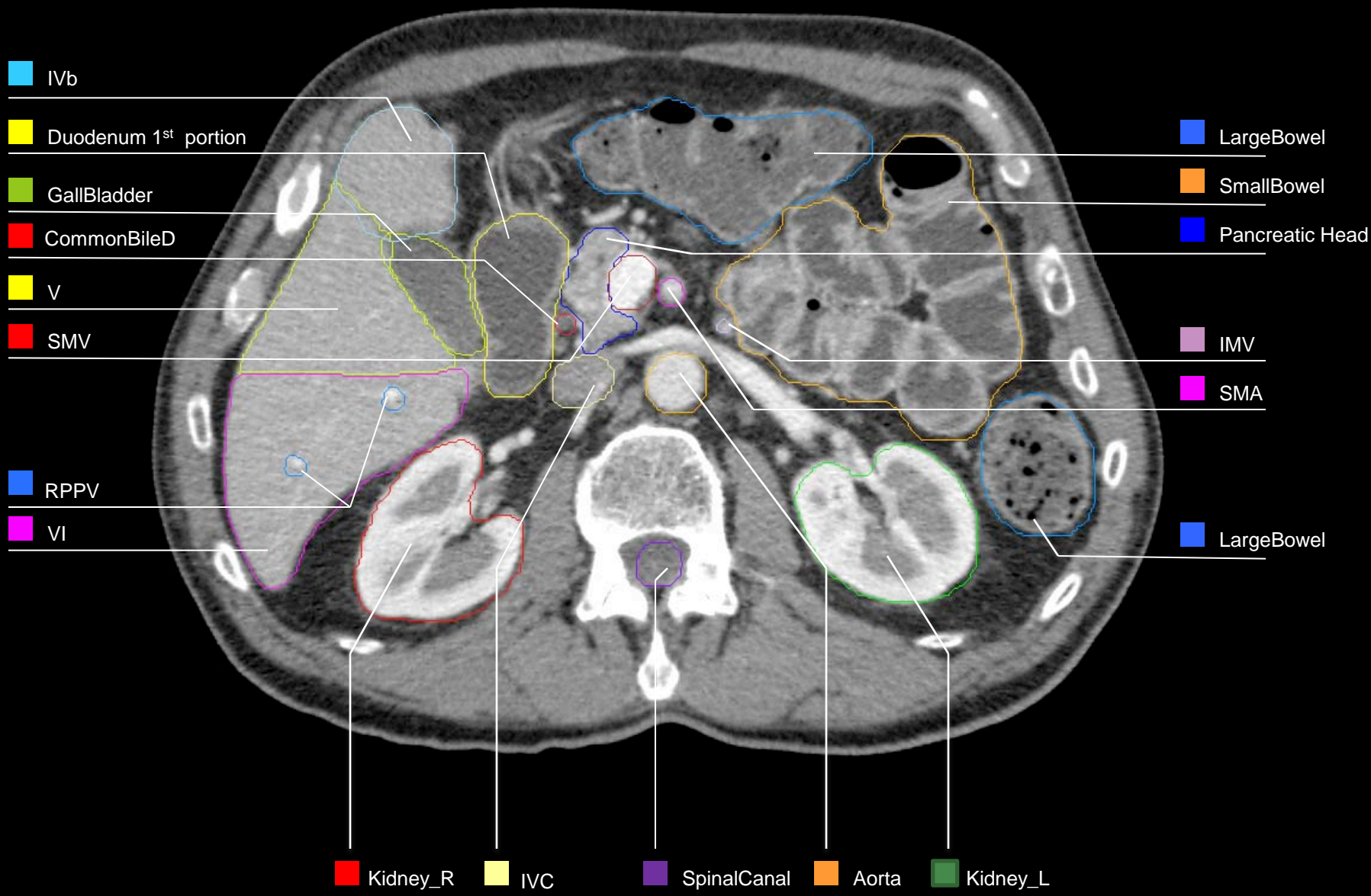


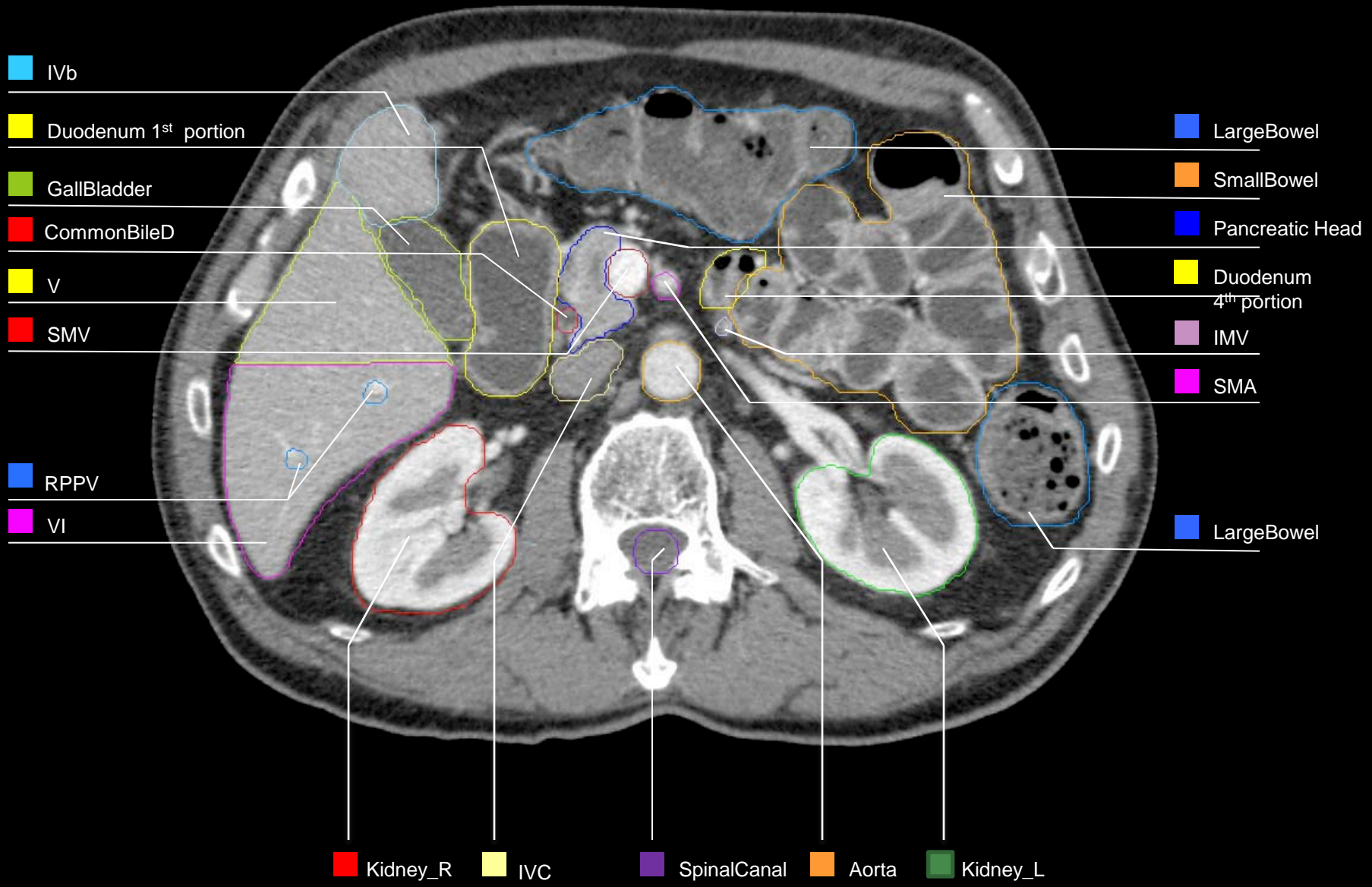


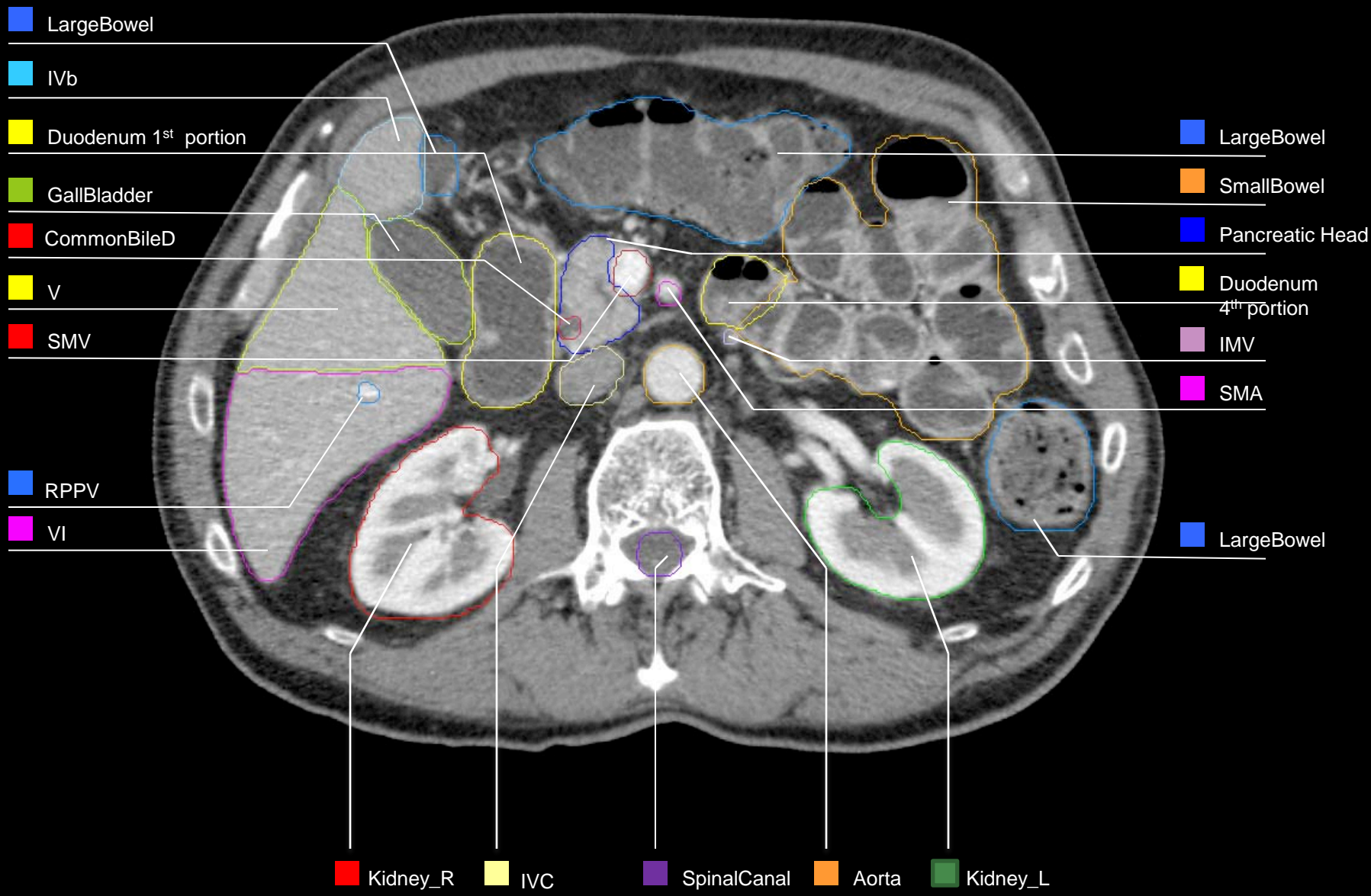


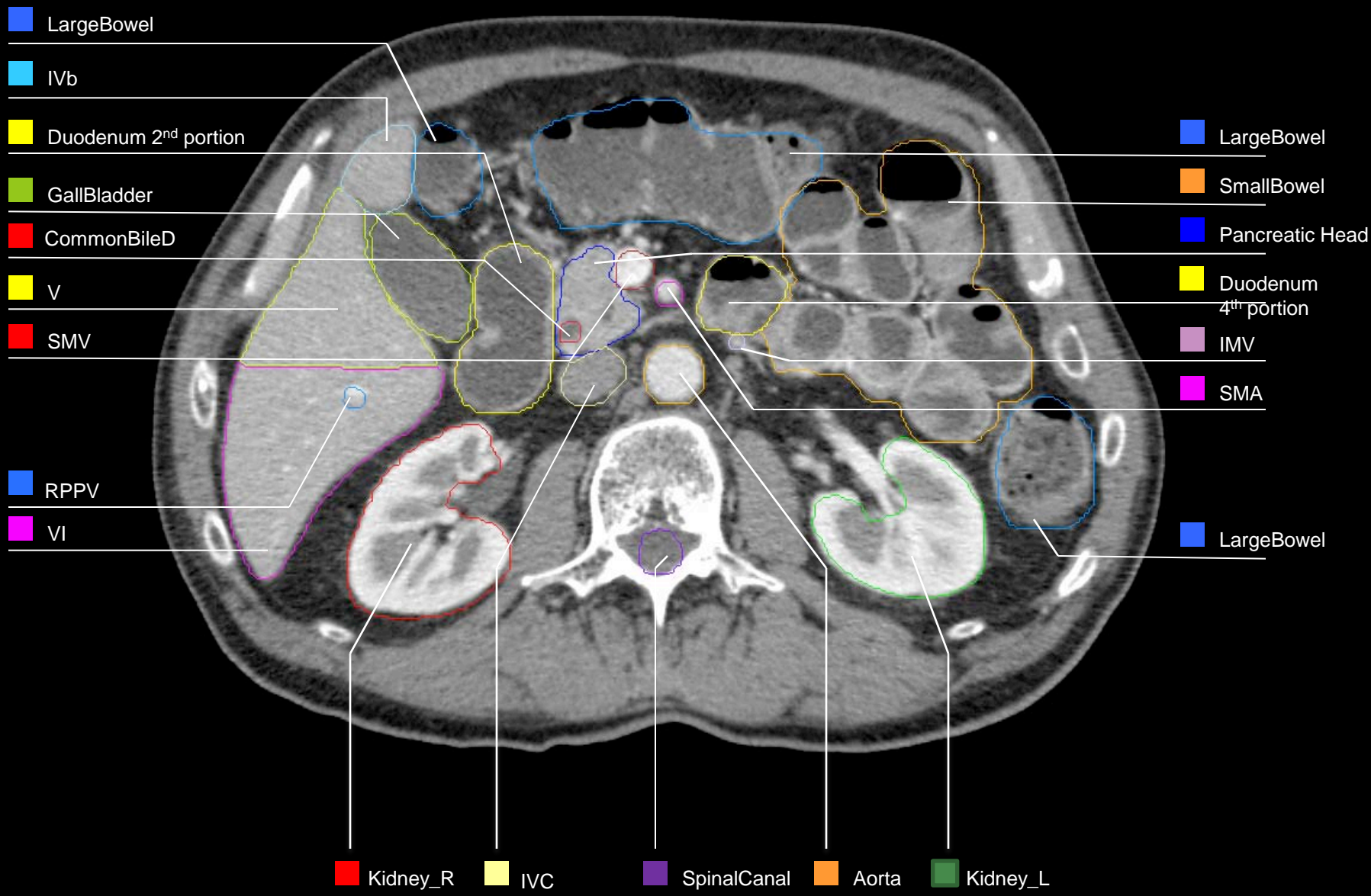


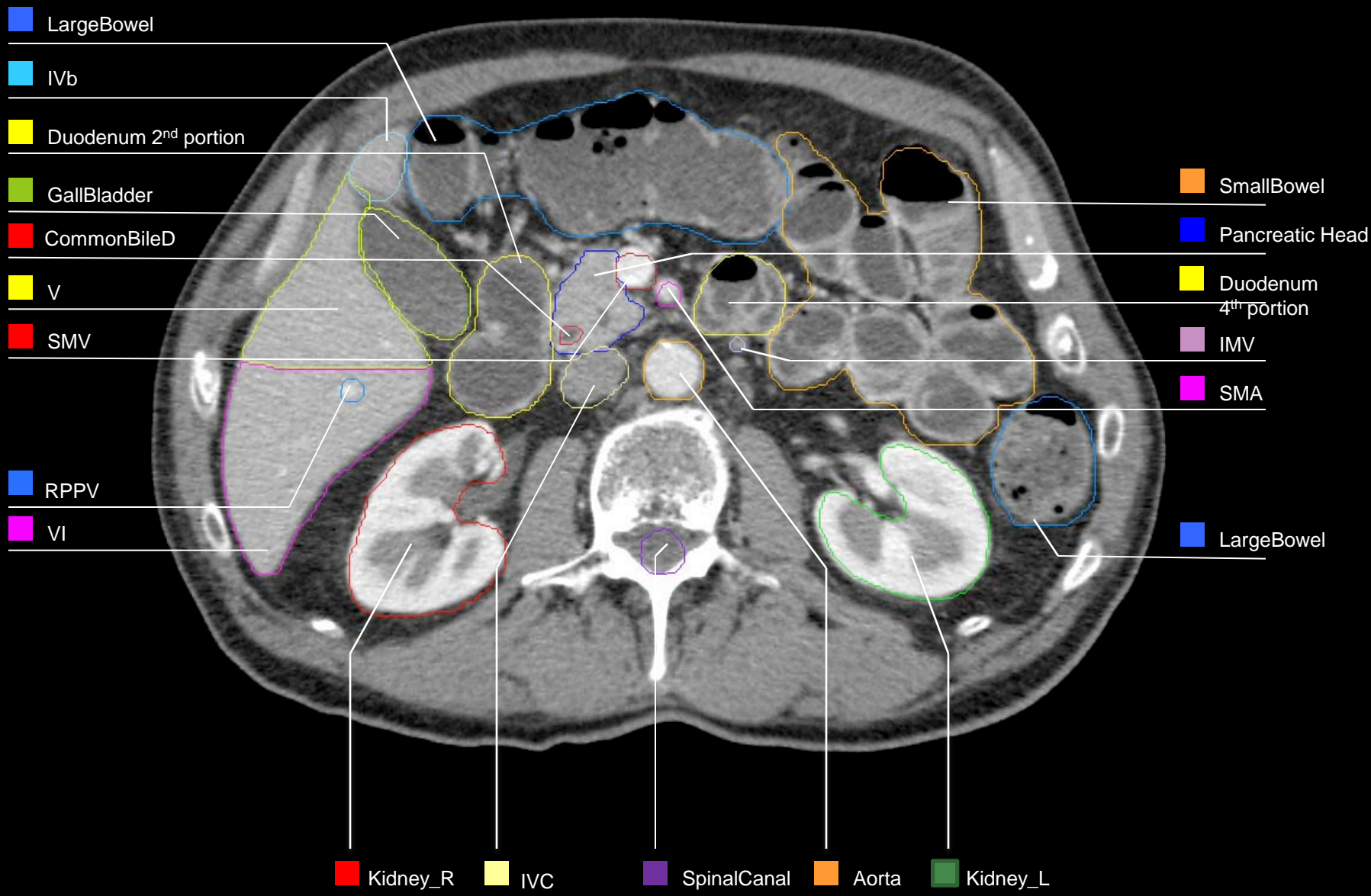


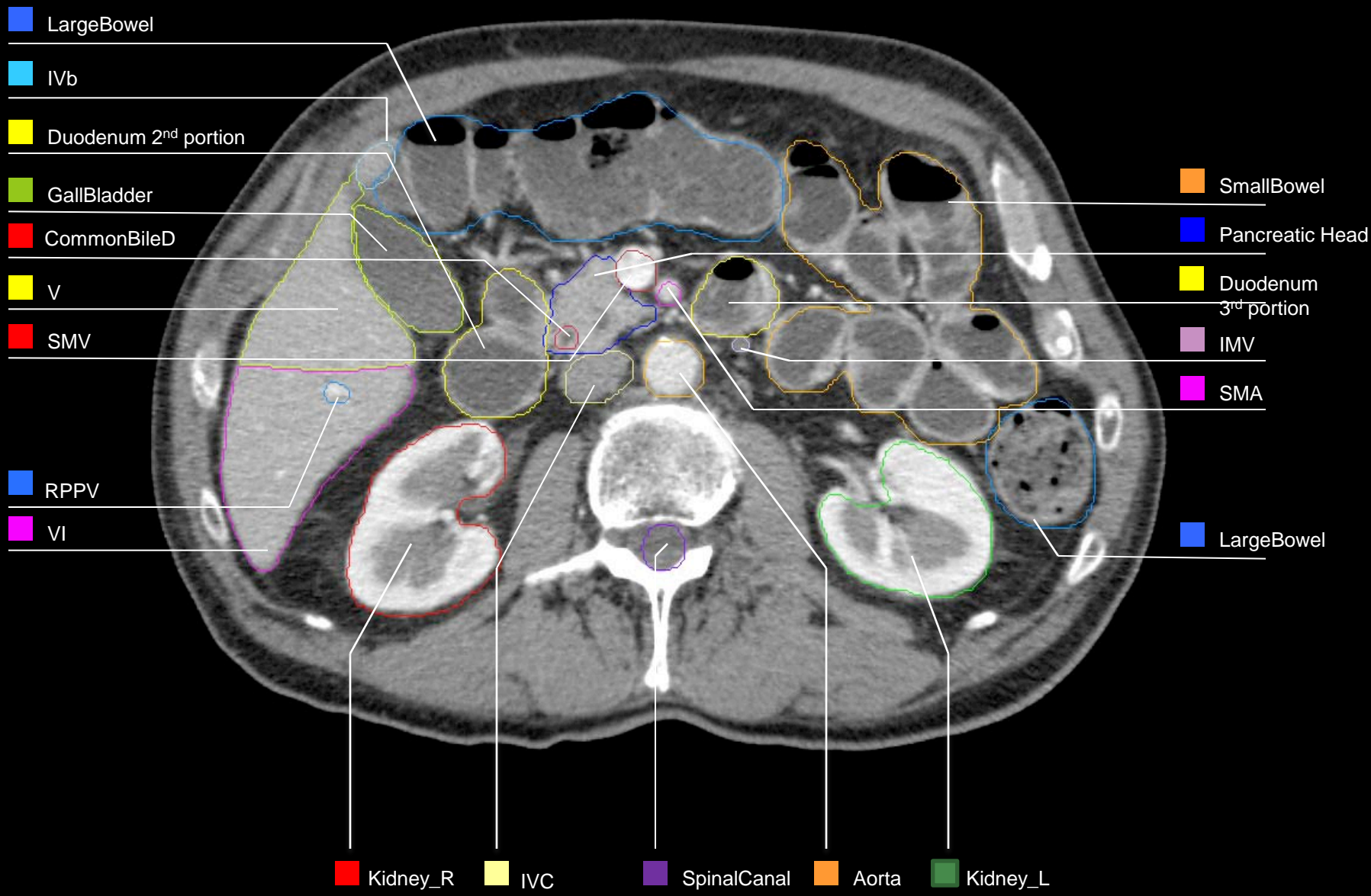


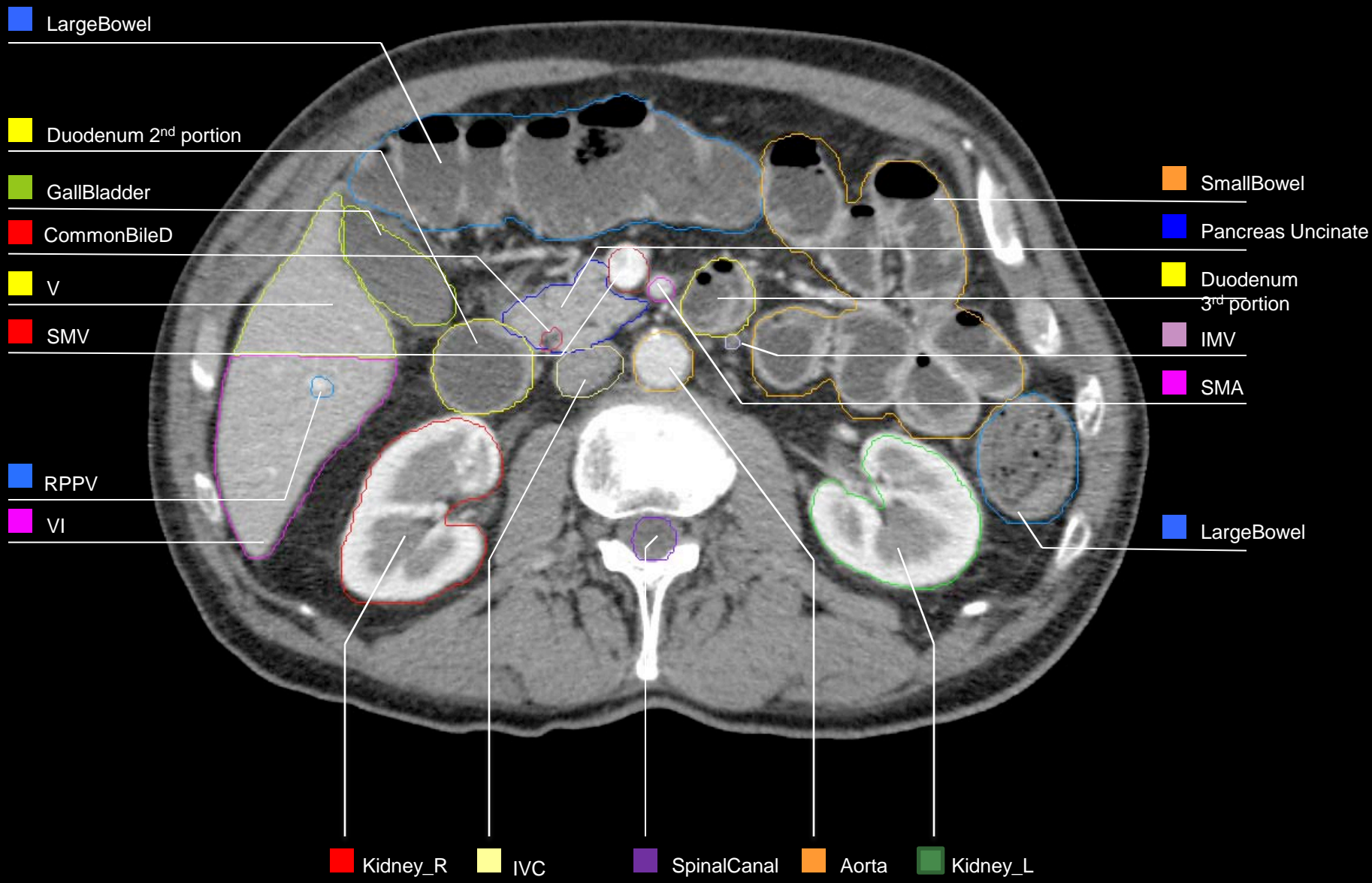


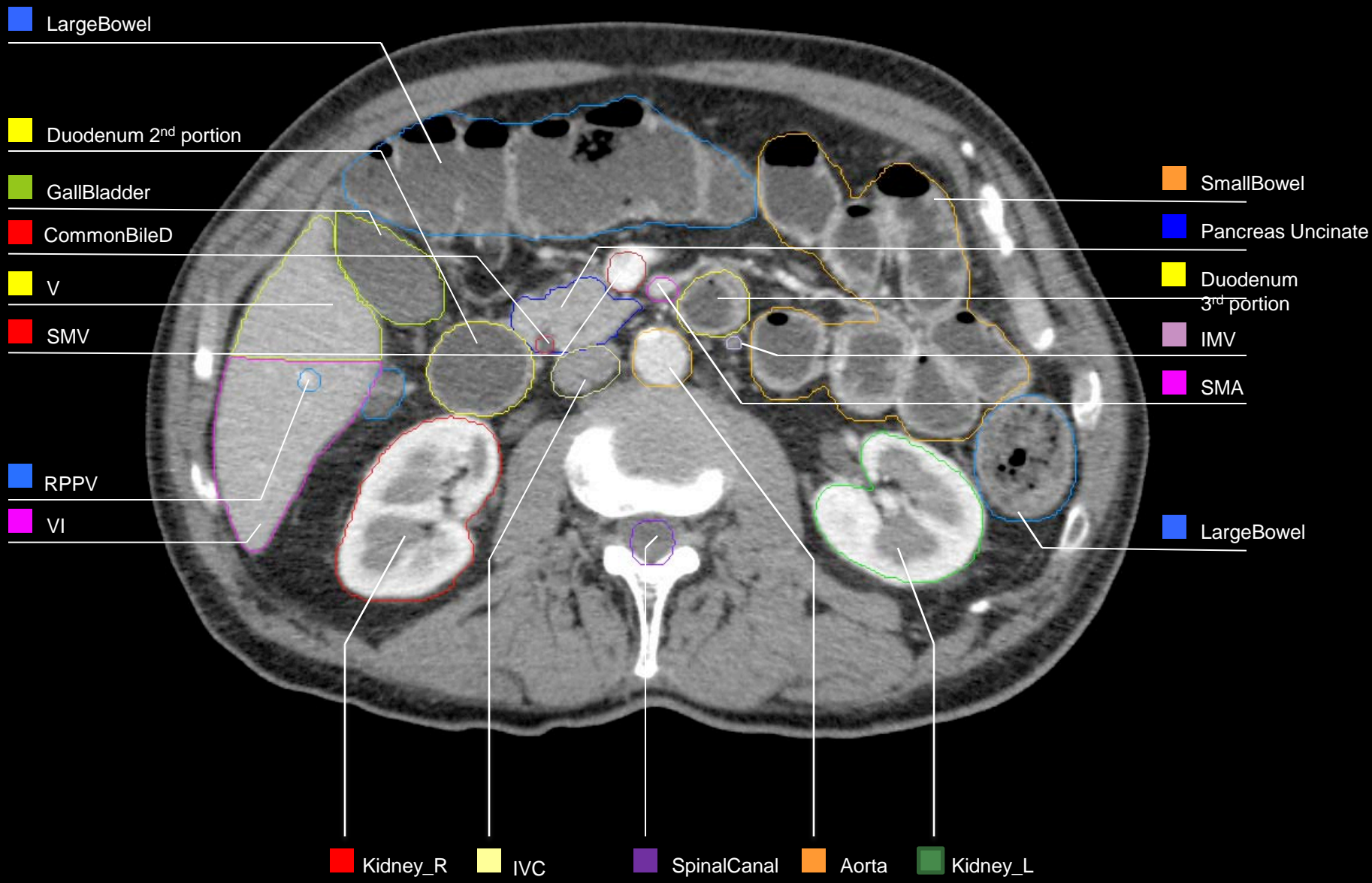


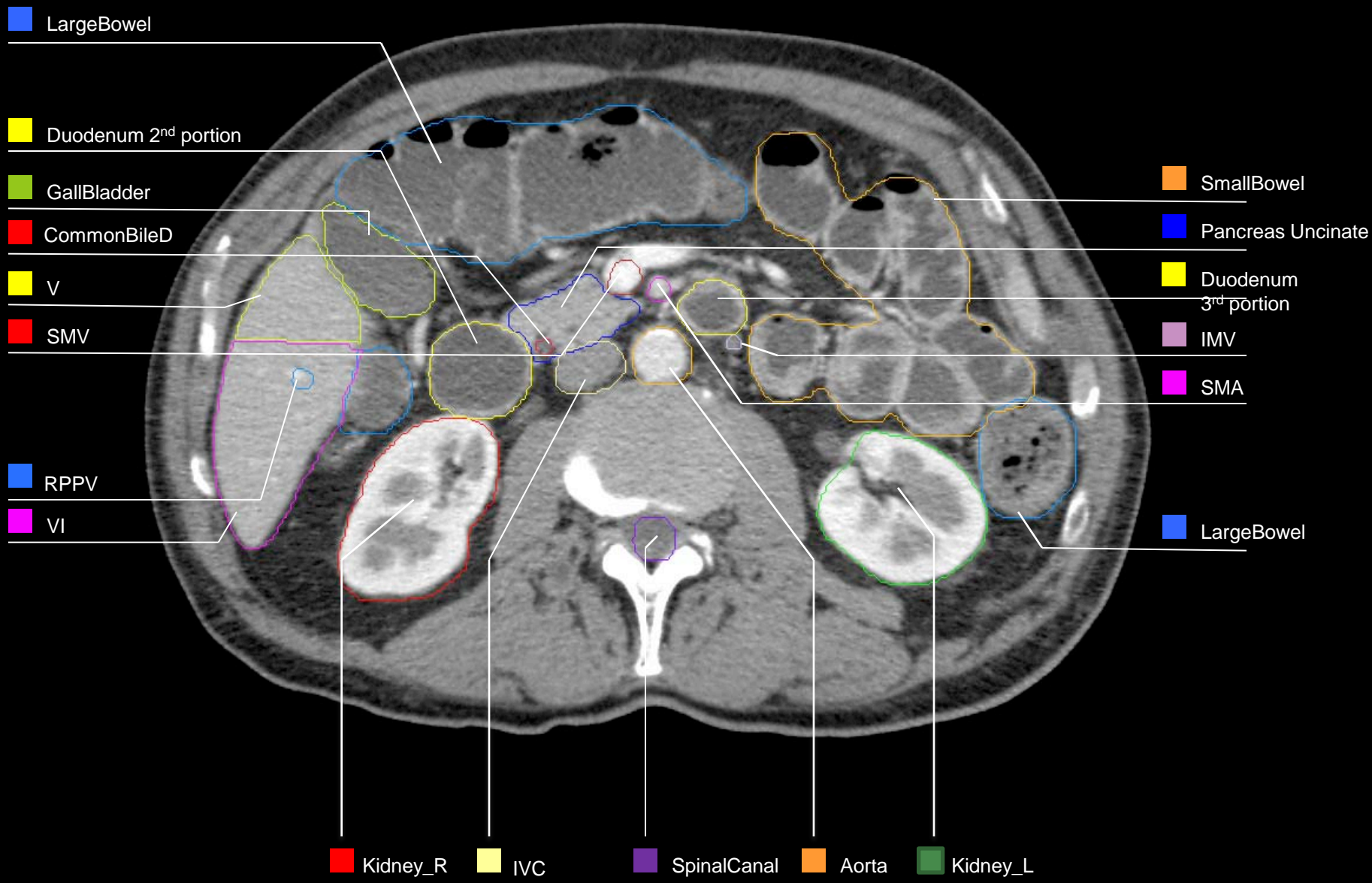


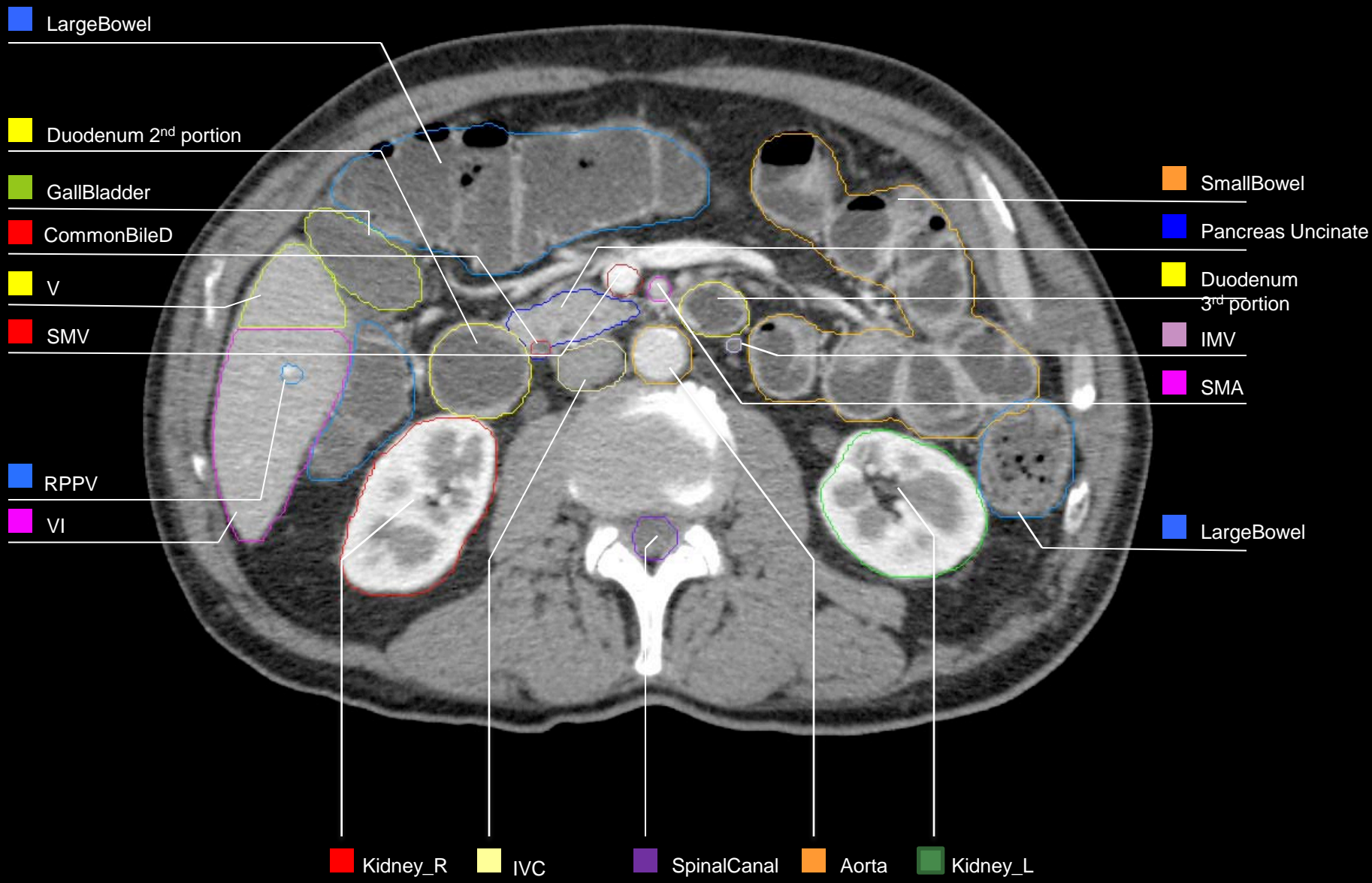


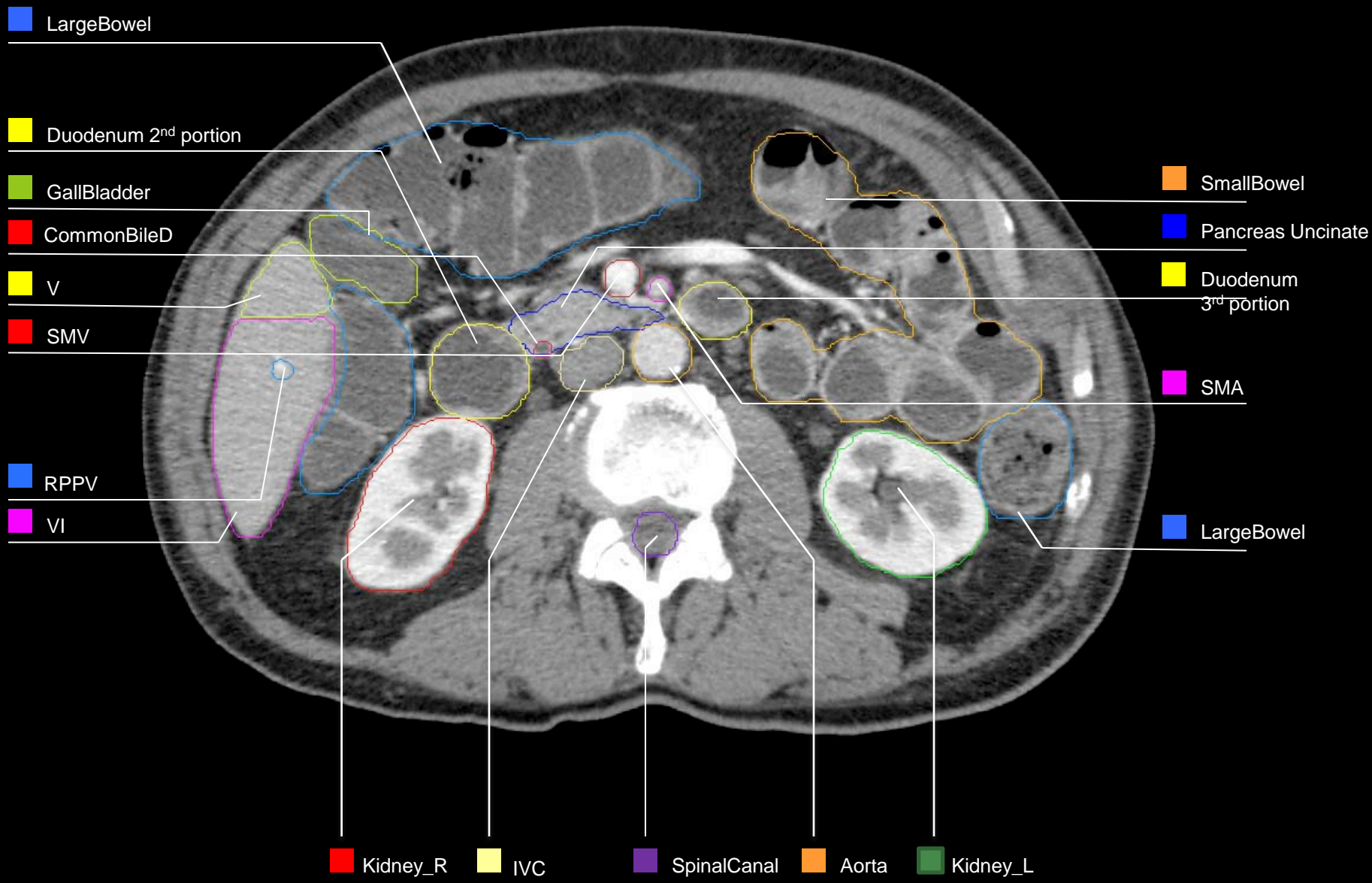


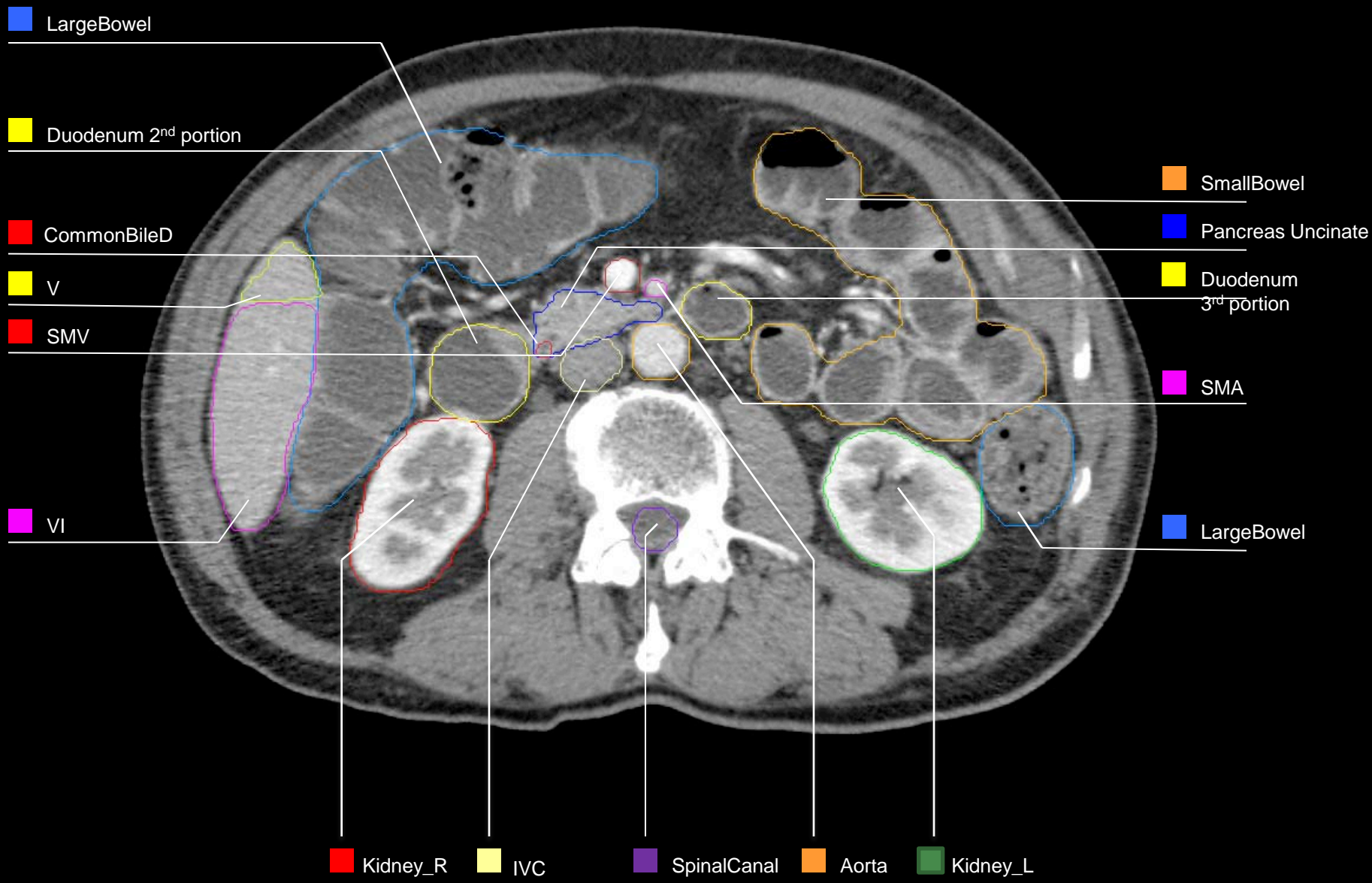


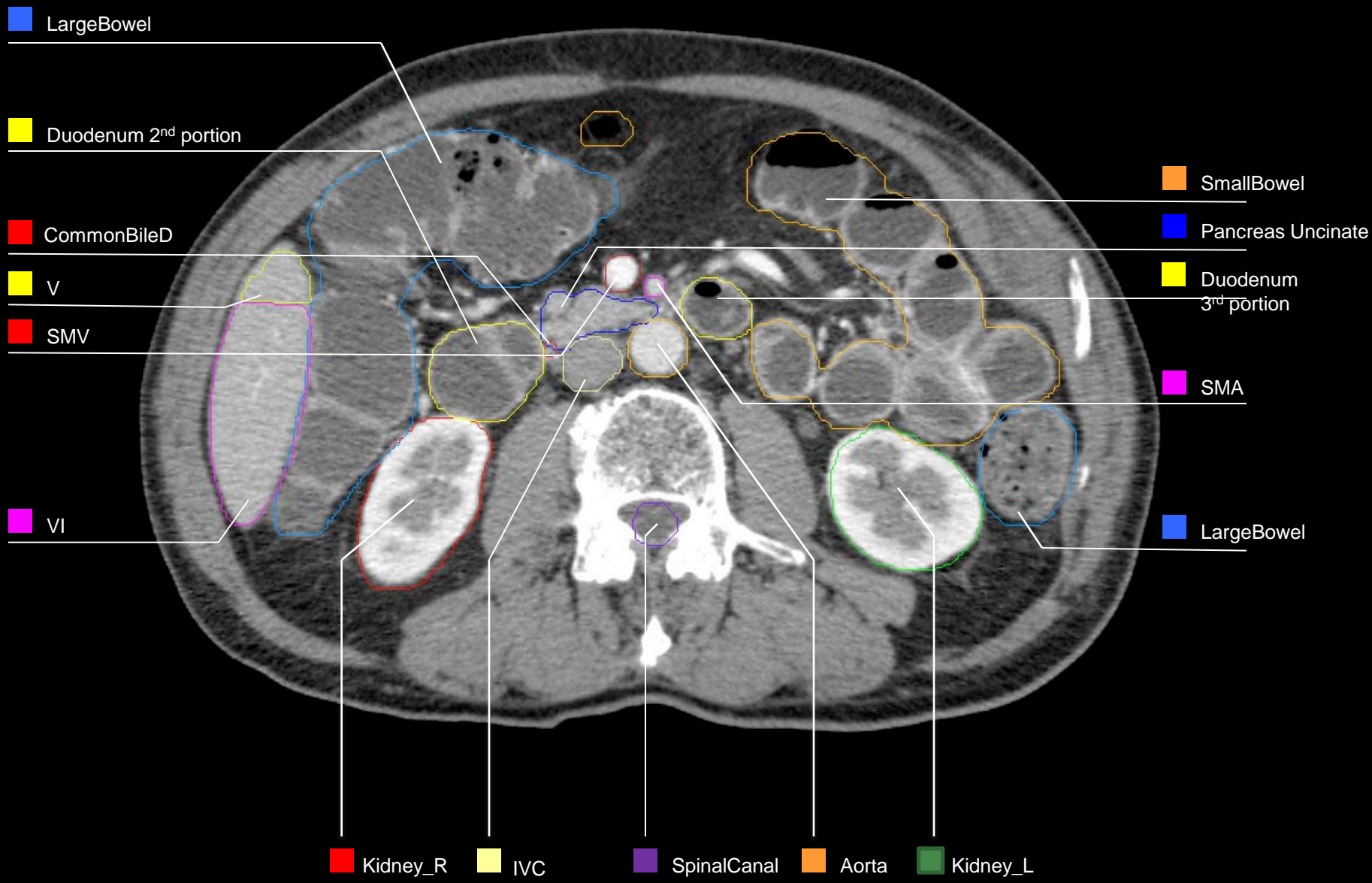


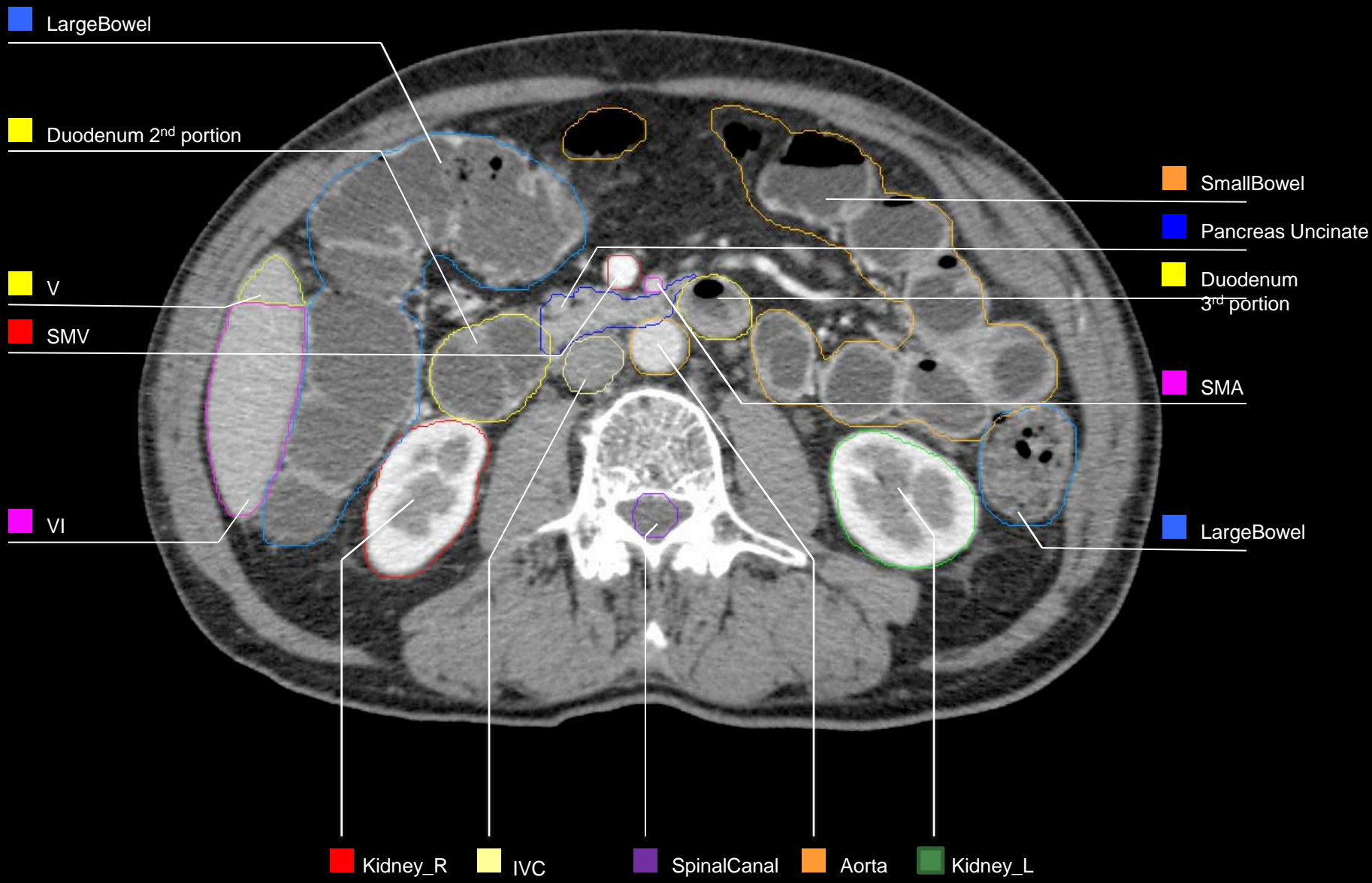


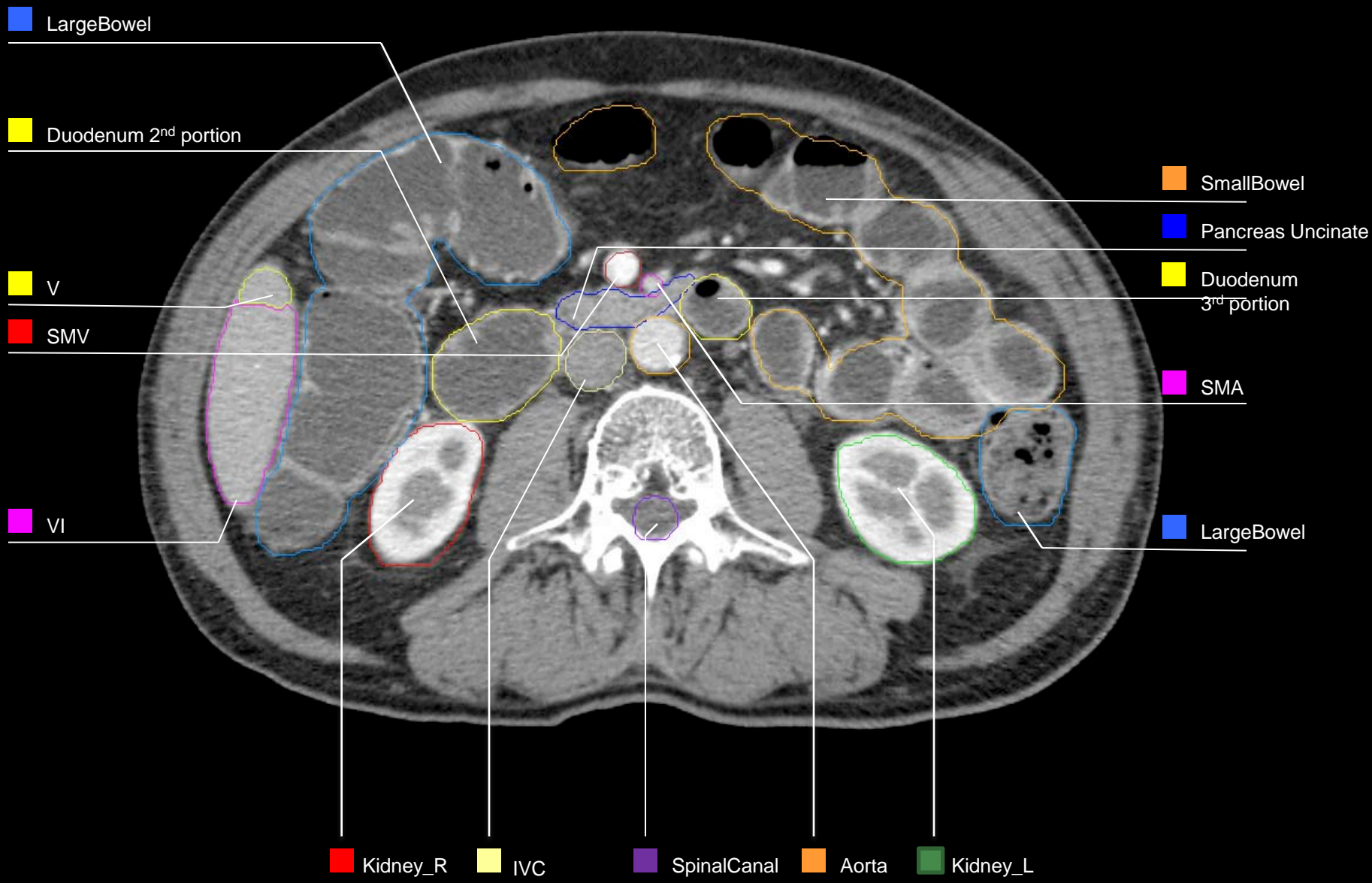


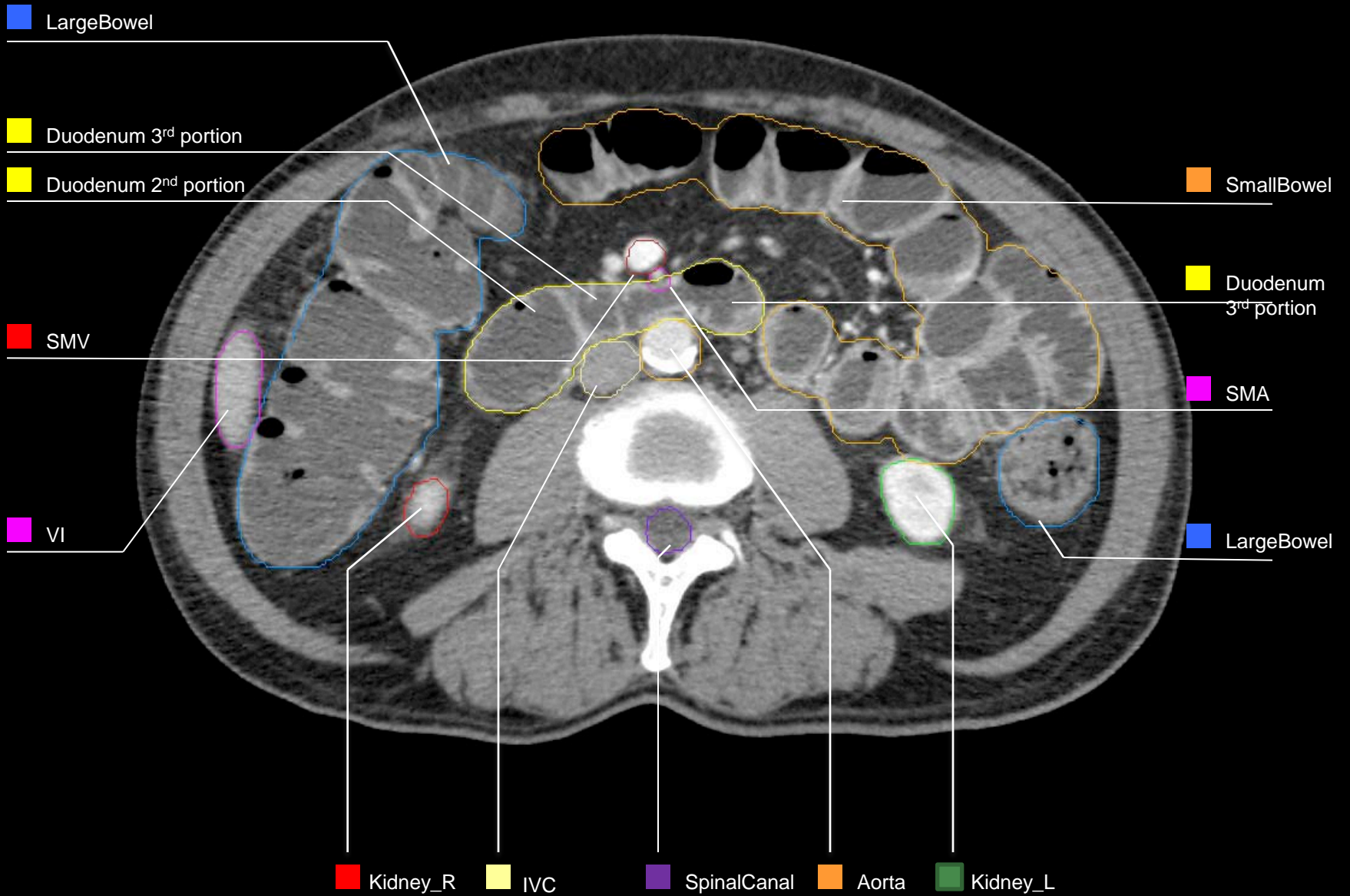




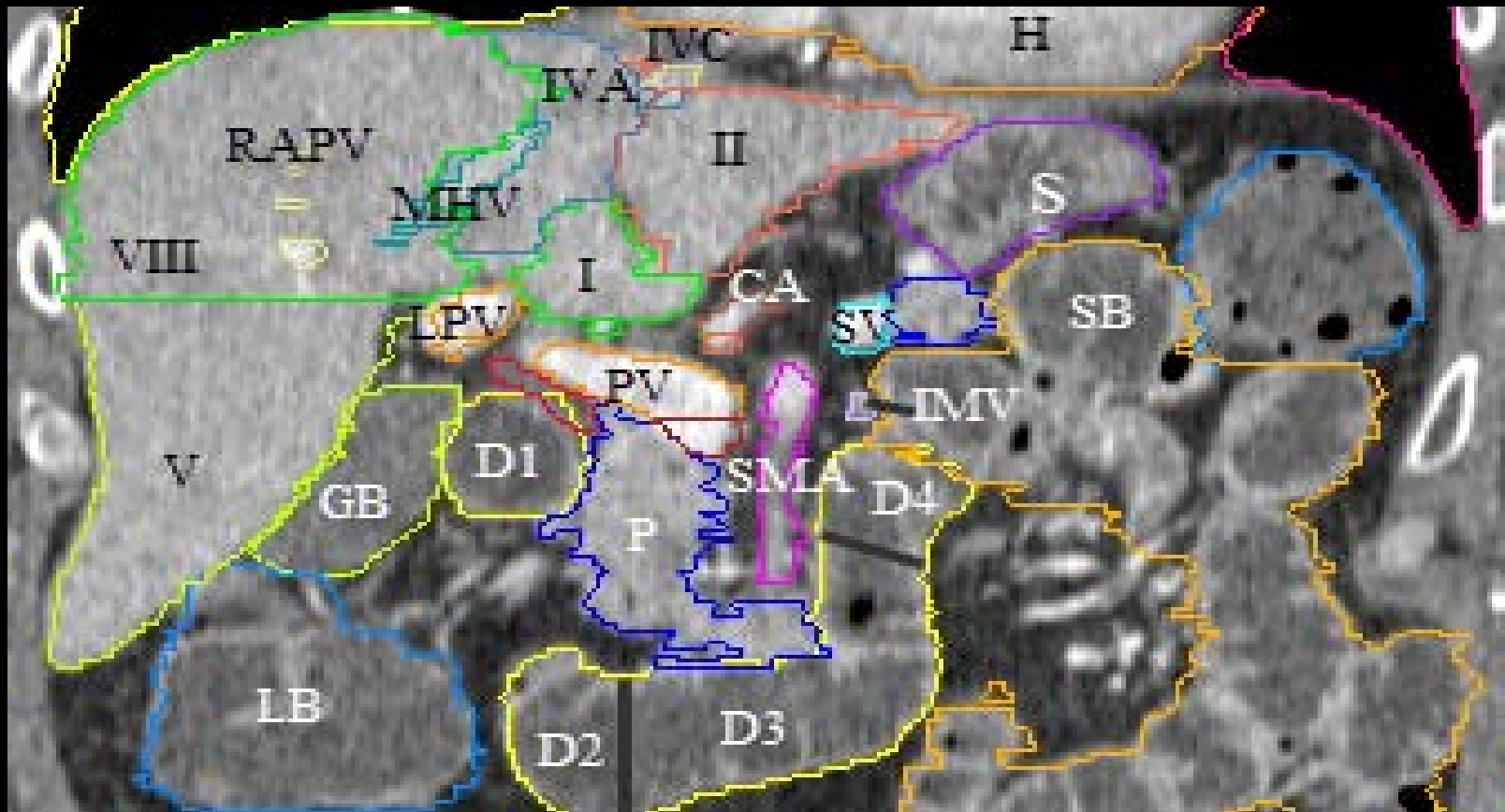








Coronal view through the four portions of duodenum



Liver

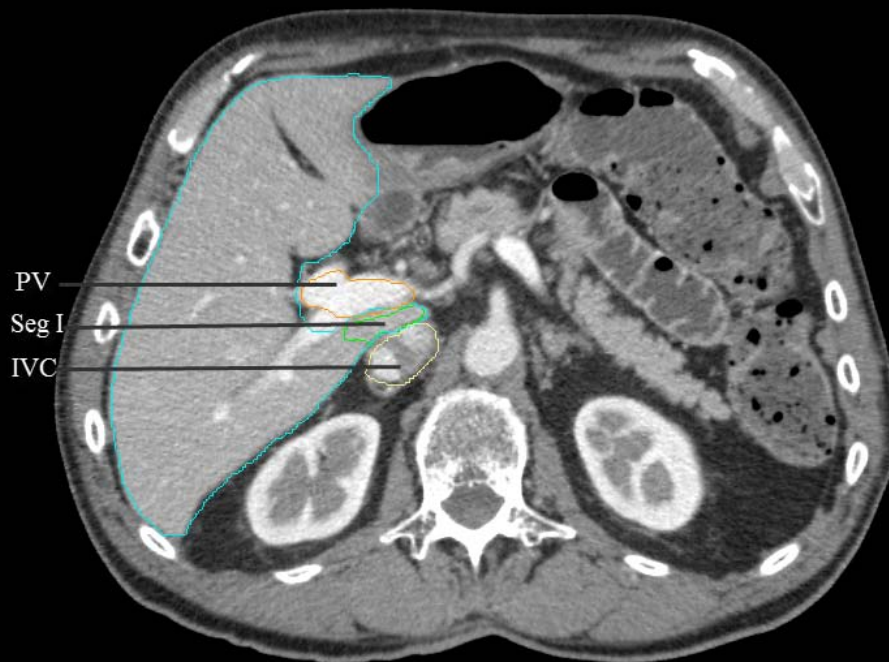
- The porta hepatis is the site of entry of the portal vein, hepatic artery, hepatic ducts, in addition to the hepatic nerve plexus and lymphatic vessels.
- The liver has a dual afferent blood supply consisting of the portal vein, the major tributary supplying 70-80% of the liver's blood supply, and the hepatic artery, which contributes to the balance.
- The hepatic artery usually arises from the celiac artery, but common variants arise from the SMA.
- There are usually three hepatic veins (right, middle, left), which collect blood from the liver to the IVC at the confluence of the hepatic veins just below the diaphragm.

Liver

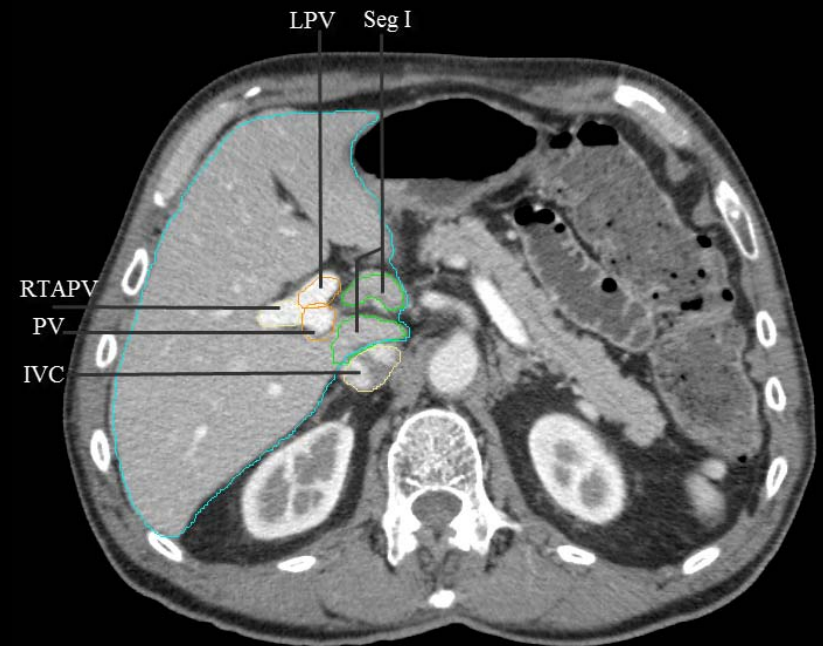
- There are 8 hepatic segments, beginning with the caudate lobe (Seg 1, part of left lobe functionally) and moving clockwise on a coronal view.
 - The left lobe of the liver includes
 - segment II (lateral superior)
 - segment III (lateral inferior)
 - segment IVA (medial superior)
 - segment IVB (medial inferior)
 - The right lobe includes
 - segment V (anterior inferior)
 - segment VI (posterior inferior)
 - segment VII (posterior superior)
 - segment VIII (anterior superior)
- The right and left lobe are separated by a plane extending vertically through the gallbladder fossa and middle hepatic vein.
- The right anterior and posterior segments are divided by a vertical plane through the right hepatic vein (V & VIII anteriorly from VI & VII posteriorly).
- The falciform ligament separates the left lateral and medial segments (II & III from IV).
- A plane of the main right and left portal vein demarcates superior from inferior segments (VII & VIII from V & VI).

For liver contouring (light blue contour below),

- Gallbladder should be excluded
- IVC should be excluded when it is discrete from the liver
- The portal vein (PV) should be included in the liver contour when Segment (Seg) I (caudate lobe) is seen to the left of PV.



e.g. Seg I is primarily posterior to PV,
so liver contour should exclude PV



e.g. Seg I is left of PV, so the liver
contour should include PV

Portal Vein (PV)

- PV is formed behind the pancreatic neck by the intersection of the SMV and SV
- PV is located posterior to the common bile duct and hepatic artery
- PV bifurcates into RPPV, RTAPV and LPV
- The left gastric vein enters the PV near its SV/PV confluence

Pancreas

- The pancreas sits at the level of L1-L3.
- The pancreatic head sits to the right of the SMA.
- The uncinate process, an extension of the head of the pancreas, is posterior to the SMV, which abuts the aorta posteriorly.
- The pancreatic body is between the celiac trunk and SMA, where it lies anterior to the aorta.
- The pancreatic tail is to the left of the SMA and SMV.

Gastro-esophageal Junction (GEJ)

- The GEJ is marked on the mucosal surface by the Z line, the boundary between the squamous esophageal mucosa and the gastric columnar mucosa.
- On axial imaging, the GEJ may appear thickened, at the level of the lower esophageal sphincter (LES).
- The GEJ should include the most distal esophagus and its interface with the cardia of the stomach.

Stomach

- The stomach (contoured as 1 organ) includes:
 - Cardia: begins at the GEJ. The lesser and greater curvatures of the stomach intersect here.
 - Fundus: most cephalad , abuts the left hemi-diaphragm, left & superior to cardia
 - Body: central, largest portion
 - Antrum: gateway into the pylorus (the sphincter opening to the duodenum)
- Oral contrast or water is recommended for optimal delineation of the gastric wall.

Duodenum (see coronal view)

- 1st portion: begins after the pylorus, is retroperitoneal after the 1st approximate 5 cm where it is suspended by hepatoduodenal ligament.
- 2nd (descending) portion: starts at superior duodenal flexure, is attached to the head of pancreas, is about 7.5 cm long, located to right of the IVC at levels L1 to L3.
- 3rd (transverse) portion: crosses in front of the aorta & IVC and is posterior to the SMA & SMV, is about 10 cm, and marks the end of the C-loop of the duodenum.
- 4th (ascending) portion: travels superiorly until it is adjacent to the inferior pancreatic body, is about 2.5 cm long, lies anteriorly to the IMV until the IMV moves medially at the transition to the jejunum.

References

1. Federle MP, Rosado-de-Christenson ML, Woodward PJ, et al. Diagnostic and Surgical Imaging Anatomy: Chest, Abdomen, Pelvis. 1st edition, Lippincott Williams & Wilkins; 2006
2. Clinically Oriented Anatomy. Keith A. Moore, Williams & Wilkins; 3rd edition; 1992.
3. Gray, H. Anatomy of the Human Body. Edited by Warren H. Lewis, 20th Edition. Philadelphia: Lea & Febiger, 1918; New York: Barlteby.com, 2000.